



5th Vet. Med. Conference  
12-14 Sept 2000 Sharm El Sheikh  
South Sinai - AR EGYPT

# Fifth Scientific Veterinary Medical Conference

The Role of Veterinary Medicine in the Development  
of Animal Wealth and Public Health Protection



5th s.c.  
12-14 Sept. 2000  
Sharm El-Sheikh  
South Sinai - A.R. EGYPT

## SCROTAL BIOMETRY AND HISTOMORPHOLOGICAL EXAMINATION OF THE TESTIS AND EPIDIDYMIS FOR CLASSIFICATION AND SELECTION OF YEARLING RAMS

M. E. A. Abou - El-Roos , A. E. Abdel -Ghaffar and A. Selmi \*

Department of Theriogenology ( Moshtohor & Zagazig\*)

Faculty of Veterinary Medicine, Zagazig University

### ABSTRACT

The present study was conducted on yearling rams (n= 30) to determine the relationship between scrotal circumference (SC) and histomorphological features of the testis and epididymis. They were selected from those slaughtered at the local abattoir and had chest girth measurements of 48 to 50 cm, but with variations in SC. Measurements of SC was determined by using a metric tape. Following clinical examination, rams were slaughtered and both testes and epididymis were excised and weighed. Specimens from the right testis and the respective epididymis were fixed and prepared for histopathological examination.

The results revealed that SC was closely correlated to testes weight (r=0.975), percentage of seminiferous tubules exhibiting the presence of elongated spermatids (r=0.944), as well as testis score (r=0.917). A positive high correlation was also existed between testicular weight and either of percentage of tubules with elongated spermatids (r=0.959) or testis score (r=0.949). A comparatively low correlation was calculated between epididymal weight and either of SC (r=0.610), testes weight (r=0.614), percentage of tubules with elongated spermatids (r=0.647) or testis score (r=0.620).

Classification of the examined rams was based upon SC measurements, testes weight and testicular spermatogenic activity. Those rams with SC of 11.5 to 20cm and had testes weight up to 100 gm were classified as unsatisfactory. They exhibited either testicular hypoplasia (partial or complete) or testicular atrophy on microscopic examination of the testes. Whereas, rams with SC of 24 cm or more and had testes weight of 134 gm or more were classified as satisfactory potential breeders. They exhibited a uniform picture of normal spermatogenesis on microscopic examination of the testes.

It can be concluded that the prospective herd sires may be selected from those yearling Rahmani rams with chest girth measurements of 48 to 50 cm and had SC of 24 cm or more. Selected rams should be subjected for semen analysis before being proved.

### INTRODUCTION

Selection of the breeding males for superior genetic and reproductive traits accelerates the improvement of offspring performance and productivity (*Toelle and Robison, 1985*). Whereas, early examination for breeding soundness enables the selection of prospective herd sires at a younger age than would otherwise be possible. Moreover, early elimination of undesirable males is

economically beneficial and contributes to increased reproductive efficiency of the herd.

The maximum rate of testicular growth in rams was recorded when body weight was 23 to 27 kg (*Watt, 1972*). Whereas, testis producing potential was correlated to SC (*Ley et al., 1990*) and other testicular measurements (*Yarney et al., 1990*). However, seasonal variation in SC (*Mickelesn, 1982*) and in testis size (*Dufour et al., 1984; Xu et al., 1991 & 1993*) may lead to incorrect decision on the soundness especially in yearling rams. Therefore, breeding soundness examination should be conducted during the breeding season of rams. Moreover, elimination of rams because of hypo-orchidism should not be made before one year of age (*Roberts, 1986*).

An understanding of the pathophysiological features of rams testis would provide a further insight for selection of yearling rams. Therefore, the present study was undertaken to determine the relationship between SC and histomorphologic features of the testis and epididymis in yearling rams. Classification of rams according to the spermatogenic activity of the testis was also considered.

## MATERIAL AND METHODS

The present study utilized 30 yearling rams of the Rahmani breed which exhibiting no permanent changes in the milky teeth. They were chosen from those submitted for slaughter in the local abattoir at Sharkia and Menofia Province during the period from March to May, 2000. Selection of rams was based on chest girth measurement. The metric tape was pulled just behind the front legs and tight enough to compress the fleece over the point of measurement on the rams back. Approximate body weight was then estimated from chest girth measurements following application of the equation (body weight in kg = [(girth in cm x 0.03) + 0.9]<sup>3</sup> adopted by *Warriss and Edwards (1995)*. Rams with chest girth of 48 to 50 cm and approximate body weight of 30 to 33kg were used. Variations in scrotal sizes were also considered during selection of rams used in this study to determine the optimum SC at which a satisfactory spermatogenesis could be achieved.

Rams with scrotal asymmetry or exhibiting any physical abnormality during clinical examination were generally excluded. Measurement of SC was taken using a metric tape around the greatest diameter of the scrotum with the testes located in the lower part of the scrotum. Following slaughter and complete postmortem examination, the genital tract was grossly examined and the testes together with the associated epididymides were dissected and weighted. Specimens from the right testis (dorsal, central and ventral regions) as well as from the head and tail regions of the respective epididymis were fixed in Bouin's fluid for 24 hours then prepared for light microscopic examination.

The spermatogenic activity of the testis was evaluated by two methods. The first method used to determine the percentage of seminiferous tubules which exhibiting the presence of elongated spermatids (*Lunstra and Ehternkamp, 1988*). The second method was used to determine the testis score according to the method adopted by *Selmi (1988)*. This scoring system

consisted of 5 to zero. Scores 5, 4 and 3 were specific for seminiferous tubules exhibiting particular stages of the spermatogenic cycle. Whereas, scores 2, 1 and zero are reserved for tubules exhibiting abnormal spermatogenesis. Thus, score 5 was given for tubules contained 5 types of cellular association (spermatogonia, intermediate spermatogonia, spermatocytes, spermatids, and spermatozoa). This score is given for stage 7 or early 8 of the spermatogenic cycle. Whereas, score zero was given for tubules lined only with Sertoli cells and / or basement membrane. One hundred cross sections of seminiferous tubules (30 from dorsal, 35 from central and 35 from ventral regions of the testis) were randomly scanned for the presence of elongated spermatids as well as for scoring. Percentage of tubules with elongated spermatids was then determined and the final testis score was calculated. Head and tail regions of the epididymis were also subjected for light microscopic examination.

Correlation coefficient was determined between various measurements recorded in the present study (*Snedecor and Cochran, 1967*).

## RESULTS

The clinical and postmortem examinations conducted on selected rams revealed that the entire reproductive organs were developed. However, measurements and development of the reproductive organs were, in general, comparable to the testicular size and development (Fig. 1 & 2). Small testes (up to 60 gm in weight) exhibited a uniform picture of Sertoli cell only tubules (testis score = zero). Complete testicular hypoplasia (n= 6) was clinically diagnosed (Fig. 3) and was clearly evident on microscopic examination of the small testis (up to 60 gm in weight). A uniform picture of Sertoli cell only tubules (Fig. 4) together with Leydig cell hyperplasia (Fig. 5) were observed. Whereas, testis weighting 60 to 80 gm exhibited either the same features or showed variable patches of normal spermatogenesis interspersed with hypoplastic tubules (Fig. 6). Those rams (n=3) was diagnosed as being affected with partial testicular hypoplasia. Marked disruption in the seminiferous epithelium together with shrunken or collapsed seminiferous tubules (Fig. 7) were also observed in the testis of two rams. They were considered affected with marked testicular atrophy. However, testicular interstitial tissue and cells were either normal or exhibiting hyperplasia especially in the vicinity of Sertoli cell only tubules. Leydig cell atrophy, on the other hand, was observed in the vicinity of tubules lined only with basement membrane or exhibited marked atrophy. Therefore, rams diagnosed as being affected with testicular hypoplasia (complete or partial) or exhibiting marked testicular atrophy were classified as unsatisfactory potential breeder (group 1). Table 1 revealed that rams belonged to this group had SC ranged from 11.5 to 20 cm ( $15.7 \pm 3.4$  cm), testes weight ranged from 30 to 100 gm ( $65.7 \pm 21.3$  gm), and epididymal weight ranged from 11 to 35 gm ( $25.1 \pm 6.2$  gm). Whereas, the spermatogenic activity of the testis, as determined by the percentage of tubules exhibiting the presence of elongated spermatids (0 - 20%) and testis score (0 - 0.6), was markedly low.

On the other hand, rams with SC of 21 to 23.5 cm had paired testes weight ranged from 110 to 142 gm (Table 1) and exhibited an active picture of normal spermatogenesis on microscopic examination of the testis. Whereas, percent of

seminiferous tubules with elongated spermatids (49.6±0.9%) was low and testis score (2.5±0.3) was below the normal score of 3 to 5. Those rams were classified as a questionable (group 2). Whereas, rams with SC of 24 cm or more and had testicular weight of 134 gm or more exhibited a uniform picture of normal spermatogenesis (Fig. 8). Moreover, percentage of seminiferous tubules exhibited the presence of elongated spermatids (69.5±3.1%) and testis score (3.2 ± 0.2) were high. Furthermore, epididymal weight was much heavier in group 3 than in group 1 or 2 (Table 1) and the epididymal tubules (in the head and tail regions) were packed with spermatozoa (Fig. 9 & 10). On the other hand, the epididymal tubules was narrow, small and was void of spermatozoa especially in cases of complete testicular hypoplasia (Fig. 11&12). Moreover, the lining epithelium was low and exhibited atrophy. In cases with partial testicular hypoplasia the epididymal tubules had nearly normal lining (Fig. 13 & 14), but was either void of spermatozoa or contained disintegrated cellular matter (especially in the tail region). Whereas, the lining epithelium of the epididymal duct in cases with testicular atrophy was normal, but was thrown into folds especially in the tail region. Moreover, the epididymal tubules exhibited reduced amounts of spermatozoa (Fig. 15 & 16).

Correlation coefficient recorded in the present study (Table 2) revealed that SC was found to be closely correlated to either testes weight ( $r= 0.975$ ), percentage of tubules with elongated spermatids ( $r= 0.944$ ) or testis score ( $r= 0.917$ ). A positive correlation was also existed between epididymal weight and SC ( $r= 0.610$ ), testes weight ( $r= 0.614$ ), percentage of tubules with elongated spermatids ( $r=0.647$ ) as well as testis score ( $r= 0.620$ ). Whereas, percentage of tubules with elongated spermatids was closely correlated ( $r=0.977$ ) to testis score.

**Table (1) : The range values ( mean ± SD) of scrotal circumference (SC), paired testes weight (TW), epididymal weight (EW), percentage of tubules with elongated spermatids (%ES) and testis score (TS) in the examined rams.**

Group	No.	SC (cm)	TW (gm)	EW (gm)	%ES	TS	Testicular morphology
1	11	11.5-20 (15.7±3.4)	30-100 (65.7±21.3)	11-35 (25.1±6.2)	0-20 (7±8.7)	0-0.6 (0.16±0.22)	Sertoli cell only tubules or marked atrophy in the seminiferous epithelium.
2	11	21-23.5 (22.8±0.7)	110-142 (129.2 ±9)	22-36 (29.9±3.9)	30-63 (49.6±9)	2.1-2.7 (2.5±0.3)	Normal spermatogenic function interspersed with non functional tubules.
3	8	24-26 (24.7±0.8)	134-162 (148.9±8.3)	30-38 (34.6±2.5)	65-74 (69.5±3.1)	3.0-3.5 (3.2±0.2)	A uniform picture of normal spermatogenesis.

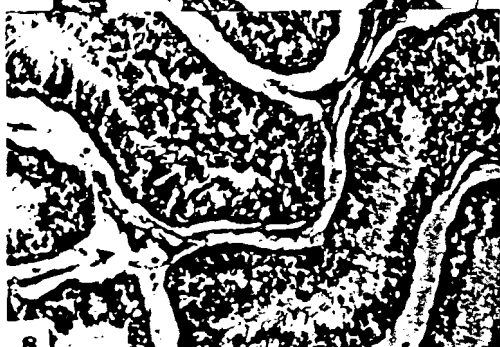
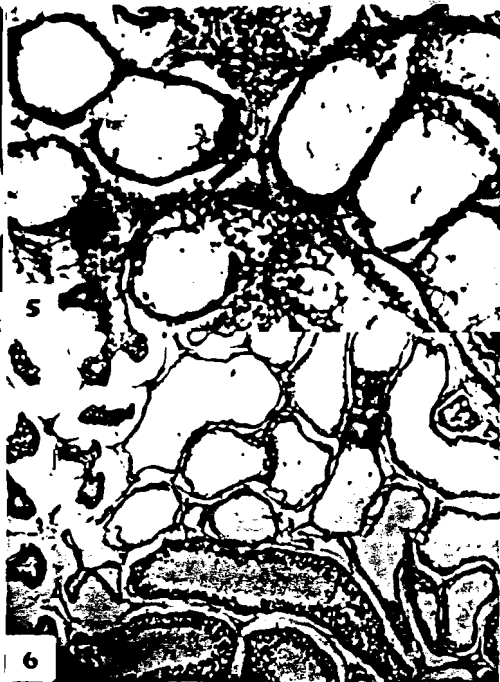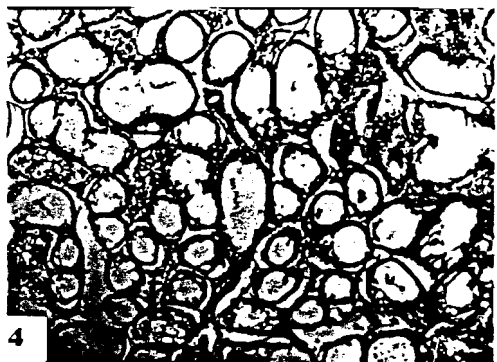

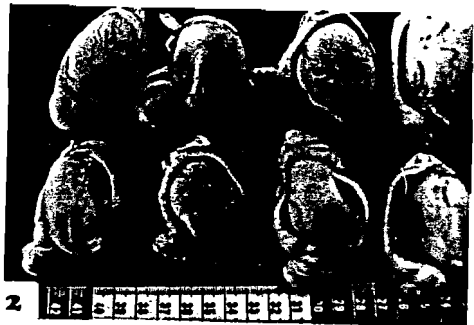
**Table (2) :Correlation coeffecient between scrotal circumference (SC) , paired testes weight (TW), epididymal weight (EW) , percentage of tubules with elongated spermatids (%ES) and testis score (TS) in the examined rams.**

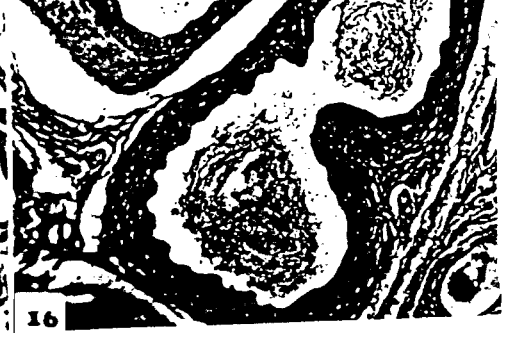
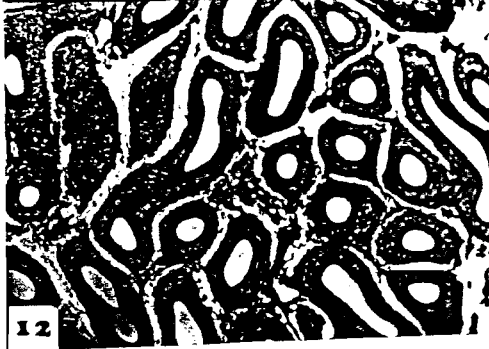
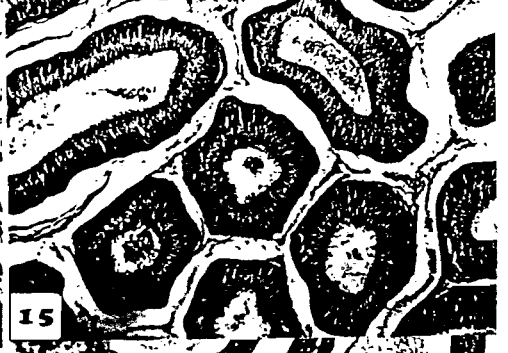
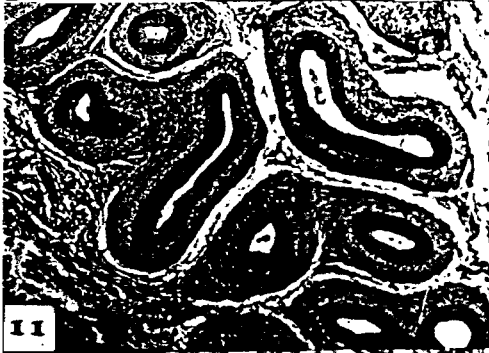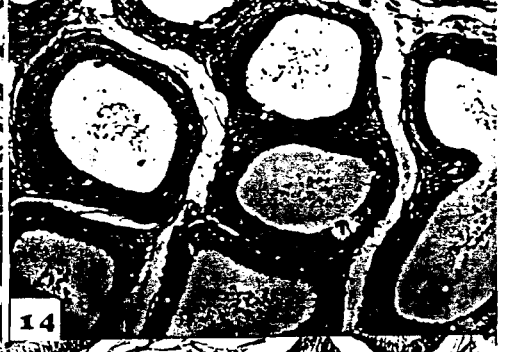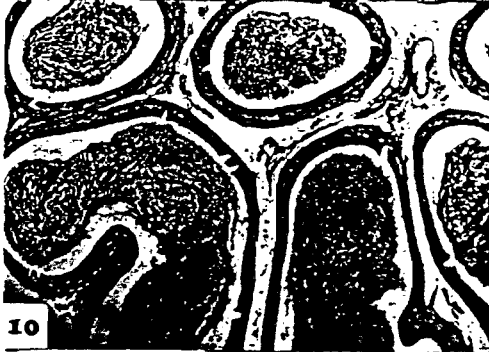
Measures	TW	% ES	TS	EW
SC	0.975	0.944	0.917	0.610
TW		0.959	0.949	0.614
%ES			0.977	0.647
TS				0.620

r values were significantly positive ( P<0.01 - 0.001)

### LEGENDS FOR ILLUSTRATION

- Fig. 1:**Photograph showing reproductive organs of rams with testicular hypoplasia (A), testicular atrophy (B), and normal testicular measurements (C)
- Fig. 2:**Photograph showing subnormal testicular and epididymal measures (hypoplasia).
- Fig. 3:**Photograph for Rahmani ram exhibited bilateral testicular hypoplasia.
- Fig.4:**Cross section (CS) in complete hypoplastic testis showing Sertoli cell only tubules (H & E, X 10 x 20).
- Fig.5:**CS in hypoplastic testis showing Leydig cell hyperplasia (H & E , X 10 x 40).
- Fig.6:**CS in partially hypoplastic testis showing hypoplastic tubules (Sertoli cell only tubules ) interspersed with normal tubules (H & E, X 10 x 20).
- Fig.7:**CS in testis showing marked atrophy in the seminiferous tubules together with Leydig cell atrophy (H & E , X 10 x 20).
- Fig. 8:**CS in normal testis showing a uniform picture of normal spermatogenesis (H & E , X 10 x 40).
- Fig. 9&10:** CS in the head and tail regions of the epididymis of normal ram showing normal lining and packed with spermatozoa (H&E, X 10x 20).
- Fig. 11&12 :** CS in the head and tail regions of the epididymis of ram affected with complete bilateral testicular hypoplasia . Notice atrophy in the lining epithelium and absence of spermatozoa ( H & E , X 10 x 20).
- Fig. 13 & 14 :** CS in the head and tail regions of the epididymis of rams affected with partial testicular hypoplasia . Notice nearly normal lining and presence of disintegrated cellular matter ( H & E , X 10 x 20).
- Fig. 15 & 16 :** CS in the head and tail regions of the epididymis of rams affected with testicular atrophy. Notice the presence of little amounts of spermatozoa , normal lining in the head and corrugated internal lining in the tail (H & E , X 10 x 20).







## DISCUSSION

Genetic improvement in male and female offspring is mostly achieved through sire selection (*Toelle and Robison , 1985* ). Clinically, selection of rams on a fixed base (chest girth of 48 to 50 cm or body weight of 30 to 33 kg) which experienced in the present study let us to select those yearling rams with satisfactory growth characteristics . Moreover, the approximate body weight selected in this study coincide with the maximum rate of testicular growth recorded by *Watt (1972)* . Since, correlation between testicular growth and body weight was much closer than between testicular growth and age *Watt (1972)* , testicular growth abnormalities could be easily recongized especially in yearling rams whose body weight is 30 to 33 kg (well grown) . Whereas, the relationship between body weight and SC is primarily due to their association with age and growth characteristics (*Rowe and Murray , 1984 ; Gojjam et al., 1995 & Nadiu and Pattabiraman, 1997* ) . Therefore, SC appears to be a key indicator trait and is considered a potentially useful indicator especially when combined with others measure of fertility. Therefore, histopathological examination was conducted in the present study to determine the relationship between SC, testes weight and the spermatogenic activity of the testes .

A positive high correlation was recorded in the present study between SC and testes weight (  $r = 0.975$  ). Similar correlations (  $r = 0.92$  and  $0.93$  ) were recorded in yearling rams (*Foster et al., 1989 & Castrillejo et al., 1995* ) . The high correlation between these parameters confirms the usefulness of measuring SC in Rahmani breed . On the other hand, the spermatogenic function of the testis was determined in the present study following application of two methods. The first method used to determine the percentage of tubules which exhibited the presence of elongated spermatids . This method coincide with the hypothesis of *Carroll and Ball (1970)* who stated that frequency of abnormal tubules provided a better measure of abnormal spermatogenesis, than did the percentage of stage 8 tubules. Moreover, the scoring system recorded in the present study (second method) revealed that seminiferous tubules with loss of only the spermatid layer (Score 3) were considered less damaged than those with loss of spermatogonia (score zero) . Thus, testis with a final score of zero was considered completely hypoplastic or severely damaged. Whereas, computerized determination of intact seminiferous epithelium area (*Rao et al., 1986*) gave a better estimate for the spermatogenic function of the testes. Thus , the scoring method is considered another alternative for computerized determination of the seminiferous epithelium area. Moreover, the positive high correlation recorded in the present study between percentage of tubules with elongated spermatids and testis score (  $r = 0.977$  ) indicating that either method may be used for successful determination of the spermatogenic function of the testis . However, diameter of the seminiferous tubules may not provide an estimate of intact seminiferous epithelium because seminiferous epithelium loss may not affect the tubules diameter except some shrinkage or changes in tubular architecture.

A positive high correlation was recorded between SC and either of testes weight (0.975) percent of tubules with elongated spermatids (0.944) or testis score (0.917). Comparable results were also presented by *Queiroz and Cardoso (1989)* who found a significant correlation between SC and either of testis

weight ( $r = 0.75$ ) or percentage of tubules containing spermatocytes ( $r = 0.80$ ). A close correlations was also recorded between epididymal weight and either of SC ( $r = 0.610$ ), testes weight ( $r=0.614$ ), percent of tubules with elongated spermatids ( $r = 0.647$ ) or testis score ( $r = 0.620$ ). Similar correlations ( $r = 0.32 - 0.94$ ) were recorded in yearling Awassi rams between testis weight, epididymal weight, testis volume, and SC (*Alkass et al., 1987*). However, SC was found to be significantly correlated ( $r = 0.76$ ) to the epididymal sperm reserves (*Alkass et al., 1987*). Moreover, epididymal sperm reserves (*Queiroz and Cardoso, 1987*) was significantly correlated with either of testes weight ( $r=0.92 - 0.94$ ), epididymal weight ( $r=0.86 - 0.99$ ) or SC ( $r=0.88 - 0.92$ ). Since, most of the epididymal weight was its contents of spermatozoa, SC measurements would provide a further insight for predicting the sperm out put of the testis and the consequent epididymal sperm reserves. This suggestion was also confirmed by the positive correlations recorded (*Martinez et al., 1984*) between SC and either of testes weight, sperm cell concentration or sperm motility. Whereas, adequate spermatogenic activity (determined by histological evaluation of the testes) recorded in the present study was observed when SC was 24 cm or more. Whileas, rams with SC less than 24 cm (irrespective of whether the testes were small, degenerated or hypoplastic) had reduced testis score and should not be selected for breeding.

It can be concluded that SC is considered a potentially useful measure for classification and selection of yearling rams. Those rams with body weight of 30 to 33 kg or chest girth measurements of 48 to 50 cm and had SC of 24 cm or more may be classified as satisfactory potential breeders and should be subjected for semen analysis before being proved.

## REFERENCES

- Alkass, J. E. ; Juma, K. H. and Mahmoud, R. A. (1987) : Testis characters and sperm reserve of horned - vs. polled sire Awassi yearling rams . Iraq J. of Agricult. Sci. , 5 : 7-14.*
- Carroll, E. J. and Ball, L. (1970) : Testicular changes as affected by mating systems in beef cattle . Am. J. Vet. Res., 31 : 241-254.*
- Castrillejo, A. ; Morana, A. ; Bielli, A. ; Gastel, T. ; Molina, J. R.; Forsberg, M. and Rodriguez- Martinez, H. (1995) : Onset of spermatogenesis in Corriedale ram lambs under extensive rearing conditions in Uruguay . Acta Vet. Scand., 36 : 161-173.*
- Dufour, J. J. ; Fahmy, M. H. and Menvielle, F. (1984) : Seasonal changes in breeding activity, testicular size, testosterone concentration and seminal characteristics in rams with long or short breeding season. J. Anim. Sci., 58 : 416-422.*
- Foster, R. A. ; Ladds, P. W. ; Hoffmann, D. ; and Briggs ; G. D. (1989) : The relationship of scrotal circumference to testicular weight in rams. Australian Vet. J., 66 : 20-22.*
- Gojjam, Y.; Gizaw, S.; Abegaz, S. and Thwaites, C. J. (1995) : Relationship between body weight and scrotal characteristics, and between environmental effects and fertility in Ethiopian Horro rams. J. Agricult. Sci., 124 : 297-299.*

- Ley, W. B.; Sprecher, D. J.; Lessard, P.; Thatcher C. D.; Pelzer, K. D. and Umberger, S. H. (1990):** Scrotal circumference measurements in purebred Dorset- Hampshire and Suffolk lambs and yearling rams . *Theriogenology* , 34 : 913-925.
- Lunstra, D. D. and Echternkamp, S. E. (1988) :** Repetitive testicular biopsy in the ram during pubertal development . *Theriogenology*, 29 : 803-810.
- Martinez, N. ; Combellas, J. ; Lopez, S. ; Rondon, Z. ; Arvelo, C. ; Perozo, D. and Mendoza, R. (1984) :** A study of some reproductive traits at different ages in West African lambs. Informe Anual, Instituto - de-Produccion - Animal, Universidad - Central - de Venezuela, P. 75-76 . Abst. Reproduced from computer Literature Search.
- Michelesn, W. D. (1982) :** Seasonal variations in scrotal circumference, sperm quality and sexual activity in rams . *J. Am. Vet. Med. Ass.*, 181 : 376-378.
- Nadiu, K. V. and Pattabiraman, S. R. (1997) :** Growth dynamics of scrotum and testis in ram lambs reared under grazing and feedlot systems. *Indian J. of Anim. Reprod.*, 18 : 142-144.
- Queiroz, G. F. and Cardoso, F. M. (1987) :** Testicular and epididymal sperm reserves of Brazilian hairy rams. *J. Vet. Med. (A)* , 34 : 657-660.
- Queiroz, G. F. and Cardoso, F. M. (1989) :** Histological evaluation of sperm production in adult Brazilian woolless rams. *Revista - Brasileira - de - Reproducao - Animal* 13 : 99-107. Abst. Reproduced from computer Literature Search.
- Rao, D. N.; Ott, R. S.; Heath, E. H. ; McEntee, K. ; Blot, D. J. and Hixon, J. E. (1986) :** Pathophysiology of small testes in beef bulls: Relationship between scrotal circumference, histopathologic features of testes and epididymides , seminal characteristics and endocrine profiles . *Am. J. Vet. Res.*, 47: 1988-1998.
- Roberts, S. J. (1986) :** *Veterinary Obstetrics and Genital Diseases* . 3rd ed., Ithaca N, Y., Published by the Author . P. 817.
- Rowe, J. B. and Murray, P. J. (1984) :** Production characteristics of rams given supplements containing different levels of protein and metabolisable energy. *Proceeding of The Australian Society of Animal Production* , 15 : 565-568.
- Selmi, A. (1988) :** Effect of photoperiod on the reproductive functions of the male . Ph. D. Thesis , Zagazig University , Zagazig - Egypt.
- Snedecor, G. W. and Cochran, W. G. (1967) :** *Statistical Methods* . 6th ed. Iowa State University Press, Ames Iowa.
- Toelle, V. D. and Robison, D. W. (1985) :** Estimation of genetic correlations between testicular measurements and female reproductive traits in beef cattle . *J. Anim. Sci.*, 60 : 89-100.
- Warriss, P. D. and Edwards, T. E. (1995) :** Estimating the live weight of sheep from chest girth measurements . *Vet. Rec.*, 137 : 123-124.
- Watt, D. A. (1972):** Testicular abnormalities and spermatogenesis of the ovine and other species . *Vet. Bull.*, 42 : 181-190.

**Xu, Z. Z.; McDonald, M. E. ; McCutcheon, S. N. and Blair , H. T. (1991) :** Seasonal variation in testis size , gonadotrophin secretion and pituitary responsiveness to GnRH in rams of two breeds differing in time of onset of breeding season . Anim. Reprod. Sci. , 26 : 281-292.

**Xu, Z. Z.; McDonald, M. E. ; McCutcheon, S. N. and Blair , H. T. (1993) :** Testis size, gonadotrophin secretion and pituitary responsiveness to GnRH in Romney rams during the transition from non- breeding to the breeding season. Anim. Reprod. Sci., 31 : 99-111.

**Yarney, T. A.; Sanford, L. M. and Palmer, W. M. (1990):** Pubertal development of rams lambs; body weight and testicular size measurements as indices of postpubertal reproductive functions. Can.J. Anim. Sci. , 70 : 139-147.

### الملخص العربي

القياس الحيوي للصفن والفحص الهستومورفولوجي للخصية والبربخ للتصنيف المبكر

وانتخاب طلائق الخراف

محمود السيد عايد أبو الروس ، علاء السيد عبد الغفار وعاطف عبد الحي خليل سلمي \*  
قسم التوليد والتناسل والتلقيح الإصطناعي بمشستر والزقازيق \* - كلية الطب البيطري - جامعة الزقازيق

أجريت هذه الدراسة علي عدد ٣٠ من ذكور الخراف وذلك لمعرفة العلاقة بين محيط كيس الصفن والمظاهر الشكلية والهستولوجية لكلا من الخصية والبربخ عند عمر سنة تقريباً. تم اختيار هذه الخراف من بين تلك التي ذبحت في المجازر وخاصة تلك التي كان لها محيط صدر يتراوح بين ٤٨ إلي ٥٠ سم مع ملاحظة وجود تباين في محيط كيس الصفن أثناء الاختيار. تم إجراء الفحص الإكلينيكي وقياس محيط كيس الصفن . ثم ذبحت الخراف وتم الفحص التشريحي للجنث وكذا الجهاز التناسلي . هذا وتم فصل الخصيتين والبربخين المتلازمين وسجلت الأوزان . كما تم أخذ عينات من الخصية اليمنى والبربخ المتلازم وجيزت لإجراء الفحوص الهستولوجية . النتائج دلت علي وجود علاقة طردية وثيقة بين محيط كيس الصفن وكلا من وزن الخصيتين (ر=٠,٩٧٥) ، النسبة المنوية للأنبيبات المنوية التي تحتوي علي طلائع المنى المستطالة (ر=٠,٩٤٤) وكذا الدرجة التقديرية لنشاط الخصية (ر=٠,٩١٧) بالإضافة إلي ذلك كانت العلاقة الطردية عالية بين وزن الخصيتين وكلا من النسبة المنوية للأنبيبان المنوية التي تحتوي علي طلائع المنى المستطالة (ر=٠,٩٥٩) والدرجة التقديرية لنشاط الخصية (ر=٠,٩٤٩) . كما وجدت علاقة طردية أقل في الحدة بين وزن البربخ وكلا من محيط كيس الصفن (ر=٠,٦١٠) ، وزن الخصيتين (ر=٠,٦١٤) ، النسبة المنوية للأنبيبات المنوية التي تحتوي علي طلائع المنى المستطالة (ر=٠,٦٤٧) ، وكذا الدرجة التقديرية لنشاط الخصية (ر=٠,٦٢٠).

الخراف المستخدمة في هذه الدراسة تم تصنيفها بناءا علي قياسات كيس الصفن، وزن الخصيتين والنشاط الحيمني للخصية . الخراف التي لها محيط كيس صفن يتراوح بين ١١,٥ الي ٢٠ سم وكان وزن الخصيتين يصل الي ١٠٠ جم كانت غير مقنعة بناءا علي وزن الفحص الميكروسكوبي للخصية والبربخ . بينما كانت الخراف التي لها محيط كيس صفن يساوي ٢٤ سم أو أكثر توافقا حيث بلغ وزن الخصيتين ١٣٤ جم أو أكثر كما أن الفحص الميكروسكوبي دل علي اكتمال النشاط الحيمني للخصية.

خلصت هذه الدراسة علي أن: انتخاب طلائق الخراف المستقبلية يجب أن يكون من بين تلك التي لها محيط صدر يتراوح بين ٤٨ الي ٥٠ سم علي أن يكون محيط كيس الصفن يساوي ٢٤ سم أو أكثر ، كما يجب أخضاعها لإجراء الفحوص المعملية لسانها المنوي قبل إجازتها كطلائق.