



BIOCHEMICAL, HISTOPATOLOGICAL AND IMMUNOHISTOCHEMICAL CHANGES IN PARACETAMOL, FISH OIL AND THIOACETAMIDE TREATED RAT

Fatma A. Gad¹, Osama A. Abd Allah², Ayman S. Farid¹, Khalid M. Fararh¹

¹Department of Clinical Pathology, Faculty of Veterinary Medicine, Benha University. ²Department of Clinical Pathology, Faculty of Veterinary Medicine, Suez Canal University.

ABSTRACT

The aim of the study is the investigation and comparison the changes in biochemical, histopathological and immunohistochemical pictures in experimentally induced different liver affections including inflammation, fatty change and cirrhosis. Six groups of rats were used; 3 groups experimentally induced hepatic stress by administration of Paracetamol (P) as single dose (1 g /kg b. wt., for 1 day) Fish oil (FO) (35% of total calories) and Thioacetamide (TAA) (200 mg/5 ml saline/Kg. b. wt.,) for 8 weeks and in addition to their controls (3 groups). Serum levels of ALT, AST and total bilirubin were significantly increased in the 3 groups. Furthermore, TAA-treated group showed significant increase in ALP and GGT as well as significant decrease in total proteins and albumin. In addition, there were disturbance in lipid profile and glucose in the three experimental groups. The results of this study demonstrated that P, FO and TAA have hepatotoxic effects, which confirmed by histopathological examinations. Hepatocytes showed hydropic degeneration in diffuse manner Also, Fatty change was observed in diffuse manner all over the hepatocytes in liver of F group. Liver in group T showed distortion of portal areas by fibrous tissue proliferation infiltrated with inflammatory cells.

Keywords: Liver functions, Paracetamol, Fish oil, Thioacetamide, hepatotoxicity

(BVMJ-25(1): 18-28, 2013)

1. INTRODUCTION

Liver is one of the most vital and target organ in the body it plays a major role in carbohydrate, protein and lipid metabolism. The liver is vulnerable to many diseases because of its strategic role and multidimensional functions. The most common worldwide liver diseases are hepatitis, fatty liver and cirrhosis [1]. Paracetamol (one of the antipyretic drugs) and Thioacetamide one of the colagoges are appeared to be hepatotoxic agents [2], and the liver response to such agents results in variety of lesions as inflammation (hepatitis) and fibrosis (cirrhosis) respectively [3]. The aim of this study is to investigate and

compare the changes in biochemical, histopathological and immunohistochemical pictures in experimental liver affections including inflammation, fatty change and cirrhosis.

2. MATERIALS AND METHODS

2.1. Animals and experimental design:

30 apparently healthy adult male white Albino rats (180–190 g.) were obtained from United Company for Chemical and Medical Preparation, Cairo, Egypt and housed for two weeks away from any stressful stimuli, and supplied with diet and water ad libitum. Rats were allocated randomly into six main groups each group consists of 5 rats: control

group for paracetamol (CP); received distilled water intragastric for only one day as a single dose. Paracetamol- treated group (P); received paracetamol intragastric at a dose of 1 gm /kg b. wt. as a single dose for one day for induction of hepatitis [4]. Control group for fish oil (CF); received distilled water intragastric for 8 weeks. Fish oil-treated group (F); received fish oil intragastric at a level of 35% of total calories (1.5 ml per rat) daily for 8 weeks for induction of fatty liver [5]. Control group for thioacetamide (CT); consists of 5 male rats and received physiological saline by intraperitoneal injection for 8 weeks. Thioacetamide-treated group (T); received thioacetamide (TAA), 200 mg/5 ml saline/Kg. i.p (3 times / week) for 8 weeks for induction of cirrhosis [6].

2.2. Chemicals

Paracetamol provided as Abimol syrup containing 150 mg paracetamol/5ml, from Advanced Biochemical Industries, El Salam City, Cairo. Fish oil obtained in a liquid form from Egypt Pharmaceutical Company. Thioacetamide was obtained as a powder form Lobachemi PVT Mumbai India.

2.3. Reagents and kits

Biochemical kits for determination of aspartate aminotransferase (AST), alanine aminotransferase (ALT), alkaline phosphatase (ALP), total protein, albumin, triglycerides, cholesterol, high density lipoprotein cholesterol (HDL-C), Serum glucose, gamma glutamyl transferase (GGT) and bilirubin were obtained from Stan Bio Laboratories. Caspase-3 antibody was obtained from Santa Cruz Biotechnology Inc, CA, USA for immunohistochemical study.

2.4. Sampling:

Blood samples were obtained from retro-orbital veinous plexus of the animals (after 1 week in paracetamol group and 8 weeks in

fish oil and thioacetamide) for sera samples. These sera were used freshly for biochemical determination of serum transaminases (ALT and AST) activities, ALP, GGT, bilirubin, total protein, albumin, glucose, cholesterol, triglycerides and HDL-C. Small tissue specimens were taken from the liver of rats in different groups and fixed in formalin after proper fixation, the specimen dehydrated in alcohol, cleared in xylene and embedded in paraffin then sections of 5 micron thickness stained by H &E and Crossman stains for histopathological and immunohistochemical studies.

2.5. Chemical analysis of serum:

All the serum biochemical parameters determined spectrophotometrically, ALT, AST, ALP GGT and bilirubin were performed according to [7,8,9, 10, 11] respectively. Total protein, albumin and HDL-C were determined by colorimetric method [12, 13, 14] respectively. Cholesterol, triglyceride and glucose were determined by enzymatic colorimetric method [15, 16, 17], respectively.

2.6. Histopathological examination:

it was performed according to the method adapted previously [18]. *Immunohistochemical examination* was performed according to the previous method [19].

2.7. Statistical Analysis

Statistical analysis was performed using the statistical software package SPSS for Windows (Version 18.0; SPSS Inc., Chicago, IL). Student's t-test was used to determine significant differences between two experimental groups. The significance of differences between more than two groups was evaluated by one-way analysis of variance (ANOVA). If one-way ANOVA indicated a significant difference, then differences between individual groups were estimated using post hoc Fisher's least

significant difference (LSD) test. Results are expressed as the mean \pm standard error of mean. A P-value of less than 0.05 was considered significant.

3. RESULTS

Data demonstrating the effects of paracetamol, fish oil and thioacetamide on serum biochemical parameters were presented in table (1). There was a significant increase in serum ALT and AST in P, F and T groups when compared on comparison with the values of the control groups. Non-significant changes were observed in ALP and GGT in P and F groups compared with control groups. Meanwhile, there was a significant increase in ALP and GGT in T group compared with control group. The serum total bilirubin, direct and indirect bilirubin showed significant increases in P, F and in T groups. Concerning to the results of total proteins, there were non-significant changes in total proteins in P and F groups compared with control groups. Meanwhile, there was a significant decrease in total proteins in T group compared with control. Table (2) represents the changes in, triglyceride, total cholesterol, HDL-C, LDL-C, albumin and glucose in paracetamol-treated group after 1 week as well as fish oil and thioacetamide-treated groups after 8 weeks. There was a significant decrease in albumin in group T compared with control. Meanwhile non-significant changes were reported in albumin in P and F groups compared with control groups. Regarding to the results of glucose, there were non-significant changes in P group compared with control groups. Meanwhile, there was a significant increase in glucose in F and T groups compared with control. There was a significant increase in triglyceride in P, F and T groups compared with control groups. Total cholesterol showed non-significant changes in P group compared with control

groups. Meanwhile, there was a significant decrease in total cholesterol in F group compared with control group, but total cholesterol revealed significant increase in T group compared with control. In comparison to the control groups, there was a significant decrease in HDL cholesterol in P and F groups. Conversely, there was a significant increase in HDL cholesterol in T group compared with control group. Concerning to the results of LDL-C cholesterol, there were non-significant changes in P group compared with control group. Meanwhile, there was a significant decrease in LDL-C cholesterol in F group compared with control but, LDL-C cholesterol showed significant increase in T group compared with control group. In histopathological examination P group, hepatocytes showed hydropic degeneration in diffuse manner after 7 days (fig. 1). Also, Fatty change was observed in diffuse manner all over the hepatocytes after 8 weeks in liver of F group (fig. 2), liver showed distortion of portal areas by fibrous tissue proliferation infiltrated with inflammatory cells and extended in between hepatic parenchyma and forming pseudo lobules, also marked congestion of portal vein and perivascular edema admixed with inflammatory cells with fibrous tissue proliferation in portal area particularly around bile ducts (fig. 3). Also, liver of this group showed positive green coloration of fibrous tissue proliferation in portal areas with marked lobulation of hepatic parenchyma as recorded by Crossman stain (fig. 4). Meanwhile, the results of immunohistochemical examination liver of P group showed severe expression for Caspase-3 in endothelial of the central vein and blood sinusoids with occasional marked expression in some hepatocytes (fig. 5). In addition, liver of rat in F group showed severe expression for Caspase-3 in the endothelium of central vein and blood sinusoids and in small numbers of hepatocytes (fig. 6). On the other hand, liver of rat in T group showed severe cytoplasmic

Table (1) Serum biochemical parameters in different treated groups compared to their control (mean \pm SE) (after 1 week in paracetamol, 8 weeks in fish oil and thioacetamide groups).

Parameters & Groups	ALT (U/I)	AST (U/I)	ALP (U/I)	GGT (U/I)	Total protein (g/dl)	Total bilirubin (mg/dl)	Indirect bilirubin (mg/dl)	Direct bilirubin (mg/dl)
Cp	27.01 \pm 0.28	49.36 \pm 0.47	85.91 \pm 0.12	2.79 \pm 0.03	6.19 \pm 0.21	0.41 \pm 0.02	0.15 \pm 0.02	0.25 \pm 0.00
P	40.04* \pm 0.35	70.96* \pm 0.35	86.21 \pm 0.26	2.75 \pm 0.03	5.90 \pm 0.11	1.09* \pm 0.14	0.37* \pm 0.02	0.70* \pm 0.12
CF	28.76 \pm 0.22	49.10 \pm 0.27	86.03 \pm 0.34	2.19 \pm 0.02	6.39 \pm 0.16	0.49 \pm 0.00	0.19 \pm 0.00	0.29 \pm 0.00
F	38.88* \pm 0.24	60.78* \pm 0.46	85.77 \pm 0.35	2.21 \pm 0.03	6.43 \pm 0.07	0.85* \pm 0.08	0.30* \pm 0.01	0.55* \pm 0.08
CT	28.15 \pm 0.09	48.24 \pm 0.14	86.03 \pm 0.29	2.17 \pm 0.02	6.35 \pm 0.06	0.44 \pm 0.01	0.18 \pm 0.00	0.26 \pm 0.01
T	37.00* \pm 1.07	58.73* \pm 1.07	135.93* \pm 1.67	12.56* \pm 0.26	4.66* \pm 0.06	1.58* \pm 0.14	0.32* \pm 0.03	1.25* \pm 0.10

Data represent mean values \pm SEM (n = 5).

* ($p \leq 0.05$) with the corresponding control groups

expression for Caspase-3 in the hepatocytes and severe expression in the endothelium of central vein and blood sinusoids (fig. 7).

4. DISCUSSION

The non-steroidal analgesic-antipyretic drug, paracetamol, is one of the safest drugs when used in recommended doses, but it is capable if administrated for long periods of producing massive hepatic necrosis on acute overdose or chronic low dose [20]. Concerning serum biochemical constituents in relation to liver functions of paracetamol-treated groups, there were significant increases in ALT and AST levels. These results agreed with the previous data [21]. These changes attributed to the formation of high amount of N-acetyl-p-benzoquinimine. This acetaminophen (APAP) metabolite is a major cause of hepatocellular damage and centrilobular

hepatic necrosis [22] and these results supported by histopathological examination of liver, which showed diffuse Kupffer cells proliferation between hepatocytes, congestion of sinusoids and ballooning of hepatocytes as described previously [23]. Declaring to bilirubin level, there was a significant increase in total bilirubin. These increase mostly due to the newly developed hepatotoxic effects of paracetamol. A significant increase in the level of triglyceride agreed with the data of [24]. These findings might be due to excessive release of triglycerides [25] and / or decreased hepatic release of lipoprotein and increased esterification of free fatty acids [24]. Also, the significant decrease in HDL-C after 7 days of treatment, which agreed previous result [26]. The disturbance in HDL-C attributed to overproduction of H₂O₂ generated during the cytochrome P450-mediated microsomal metabolism of

Table (2) Serum biochemical parameters in different treated groups compared to their control (mean \pm SE) (after 1 week in paracetamol, 8 weeks in fish oil and thioacetamide groups).

Parameters & Groups	Glucose (mg/dl)	Albumin (g/dl)	LDL (mg /dl)	HDL (mg /dl)	Cholesterol (mg /dl)	Triglycerides (mg /dl)
Cp	70.77 \pm 1.87	3.46 \pm 0.11	22.13 \pm 1.22	31.19 \pm 0.96	69.10 \pm 2.03	78.61 \pm 1.32
P	71.05 \pm 0.98	3.40 \pm 0.11	30.63 \pm 4.96	26.42* \pm 1.00	77.24 \pm 5.38	100.94* \pm 3.54
CF	69.27 \pm 0.38	3.35 \pm 0.10	14.16 \pm 1.02	24.91 \pm 0.61	55.06 \pm 1.27	79.93 \pm 0.38
F	78.54* \pm 0.60	3.40 \pm 0.05	6.94* \pm 1.17	15.35* \pm 0.84	42.30* \pm 2.36	100.04* \pm 4.05
CT	71.16 \pm 1.33	3.44 \pm 0.05	16.04 \pm 0.76	23.53 \pm 0.30	55.95 \pm 0.96	81.86 \pm 0.19
T	84.35* \pm 0.47	2.28* \pm 0.12	41.93* \pm 1.69	26.20* \pm 0.14	92.63* \pm 1.77	122.49* \pm 0.71

paracetamol [27]. On the other hand, there were non-significant changes in cholesterol, glucose, and total protein. These results agreed with previous data [25]. Concerning to the immunohistochemical examination, it used for detection of caspase-3, which is important signaling molecule present in cytoplasm and has a role in the initiation and progression of apoptosis, inactive form of caspase-3 changed to active form for the detection of apoptotic events [28]. The present study indicated that liver of paracetamol-treated group showed severe expression of caspase-3 in endothelial of the central vein and blood sinusoids and low expression in the hepatocytes, which indicates that high dose of paracetamol cause low apoptosis to hepatocyte.

Fish oil is an oil derived from the tissues of oily fish. Fish oils contain the omega-3 fatty acid seicosapentaenoic acid (EPA), and docosahexaenoic acid (DHA), precursors of certain eicosanoids that are known to reduce

inflammation throughout the body [29]. In fish oil treated rats, ALT and AST showed significant increase. These results are in agreement with previous data [30]. These increases may be due to accumulation of lipid in hepatocytes lead to hepatocellular swelling and membrane damage, which lead to increase permeability and release of these enzymes to the blood [31]. These results supported by histopathological changes as the liver showed degenerative changes especially fatty changes, which increase and become diffuse by increased the duration of experiment and characterized by large vacuoles giving the cell signet ring shape pushed the nucleus to the periphery of the cells as reported previously [32]. In addition, there was a significant increase in glucose level, which may be due to decreased serum insulin level because of fish oil feeding [33]. Moreover, there was an increase in bilirubin level, which indicates hepatocellular damage because of lipid

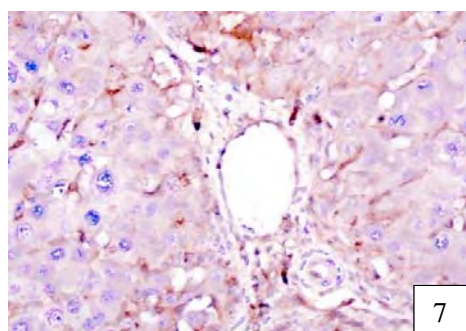
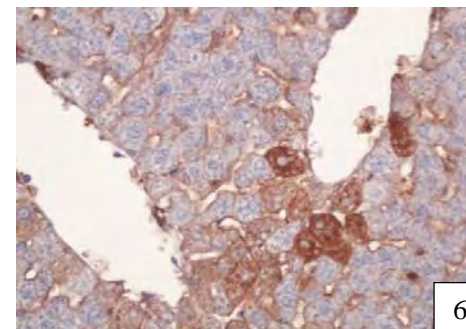
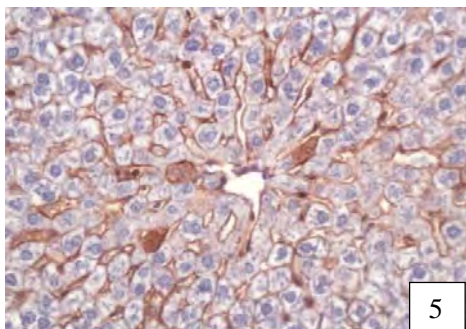
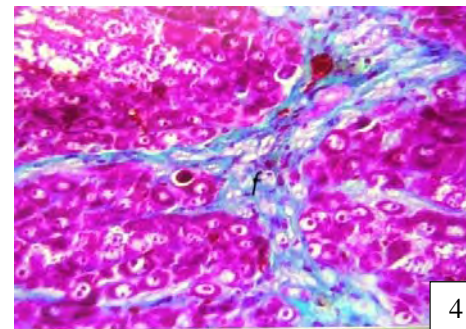
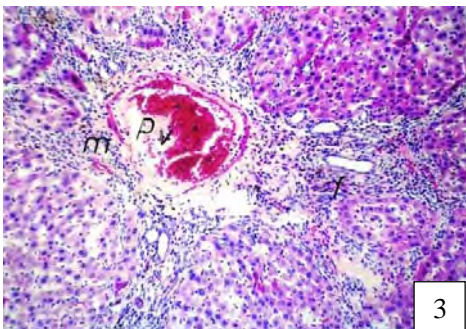
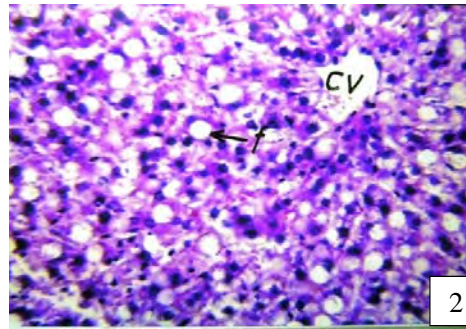
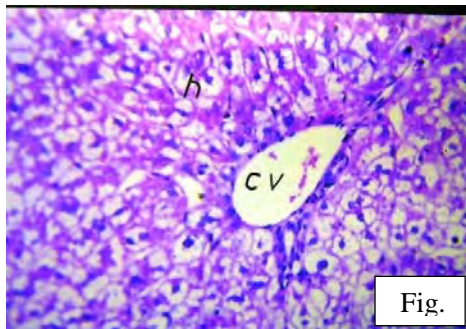


Fig (1): Liver of rats received paracetamol 1gm/kg B. wt., 7 days post treatment, showing hydropic degeneration of the hepatocytes in diffuse manner X600. Fig (2): Liver of rats received fish oil 35% of total calories; 8 weeks post treatment, showing fatty change (f) in diffuse manner all over the hepatocytes X600. Fig (3): Liver of rats received thioacetamide 200mg/5ml saline/kg B. wt.; 8 weeks post treatment, showing marked congestion of portal vein and perivascular edema admixed with inflammatory cells (m) with fibrous tissue proliferation (f) in portal area particularly around bile ducts X400. Fig (4): Liver of rats received thioacetamide 200mg/5ml saline/kg B. wt. showing positive reaction of fibrous tissue proliferation in portal

Clinicopathological study on some hepatotoxins

area as recorded by Crossman stain X400. Fig (5): Liver of rat received paracetamol 1gm/kg. B. wt., 1 week post treatment, showing sever expression for Caspase-3 in endothelial of the central vein and blood sinusoids with occasional marked expression in some hepatocytes X400. Fig (6): Liver of rat received fish oil 35% of total calories; 8 weeks post treatment, showing severe expression for Caspase-3 in the endothelial of central vein and blood sinusoids and in small number of hepatocytes X400. Fig (7): Liver of rat received thioacetamide 200mg/5ml saline/kg B. wt., 8 weeks post treatment, showing severe cytoplasmic expression for Caspase-3 in the hepatocytes and very sever expression in the endothelium of central vein and blood sinusoids X400.

accumulation in hepatocytes [31]. Regarding to the effect of FO feeding on lipid profile, there was a significant increase in triglyceride. Our results agree with the result reported previously [34] who found elevated triglyceride level in sunflower oil treated rats, which may be due to increased synthesis and secretion of lipoproteins because of hepatic hyperlipogenese. Conversely, there was a significant decrease in cholesterol, LDL-C and HDL-C levels. These results were agreed with data recorded previously [33]. This hypocholesteremic effect may be due to fish oil diet enhances the binding affinity of LDL-C to liver plasma membranes or apolipoprotein B which is the principle protein of LDL-C, comprising nearly 90% of total protein mass, and fish oil was shown to reduce apolipoprotein B. Therefore, FO reduce LDL-C [35].

With respect to the immunohistochemical examination, the present study indicated that liver of fish oil group showed severe expression of caspase-3 in the endothelial of central vein and blood sinusoids and in low number of hepatocytes, which indicates death of some hepatocytes. TAA is a potent selective hepatotoxin due to oxidative injury, which has been recognized as the major mechanism in TAA-induced liver damage [36]. There were significant elevations in ALT, AST, ALP, GGT, total bilirubin and glucose levels. Increase levels of ALT and AST may be due to AST present in both mitochondria and cytosol of liver cells, while ALT is found in cytosol only so that when liver cells damage release these enzymes into the extracellular fluid and results in increased

plasma levels of transaminases activity [37]. increased ALP and GGT levels might be due cholestasis as cholestasis implies impairment of bile flow, which can be caused by obstruction of biliary tract [38]. These results confirmed by histopathological examination where liver showed distortion of portal areas by fibrous tissue proliferation infiltrated with inflammatory cells, extended in between hepatic parenchyma, and forming pseudolobules. In addition, marked congestion of portal vein and perivascular edema admixed with inflammatory cells and fibrous tissue proliferation in portal area particularly around bile ducts. Increased total bilirubin may be due to failure of normal uptake, conjugation and or excretion by the damaged hepatic parenchyma [31], while hyperglycemia may due to effect of TAA on liver glycogen producing glycogenolysis and this was accompanied by a marked increase in serum glucose [39].

On the other hand, there was significant decrease in total proteins and albumin, which agreed with previous results [40]. It is well known that following cellular damage the capacity to synthesize proteins is reduced, and as the extent of damage increases, the levels of these proteins in the plasma will tend to decrease (total protein and albumin levels) [40]. There were significant increases in triglyceride, cholesterol, HDL-C and LDL-C. This indicates disturbances in lipid metabolism induced by TAA intoxication as reported and agreed the results recorded previously [41].

The result of immunohistochemical examination showed severe cytoplasmic

expression for caspase-3 in the hepatocytes and in the endothelium of central vein and blood sinusoids when compared with control group, which confirm the hepatotoxic effect of thioacetamide due to increased hepatic apoptosis.

Conclusion

From the present study, it concluded that paracetamol, fish oil and thioacetamide have toxic effect on liver and cause disturbance in its function, which resulted in increase in ALT, AST and total bilirubin. Furthermore, increased ALP and GGT in TAA treated-rats with alteration of serum lipid, glucose and total protein levels were recorded.

5. REFERENCES

1. Roy, C.K., Das, A.K. 2010. Comparative evaluation of different extracts of leaves of psidium guajavalinn for hepatoprotective activity. Pakistan Journal of Pharmaceutical Sciences 23(1): 15-20.
2. Saraswat, B., Visen, P.K.S., Dayal, R., Agarwal, D.P., Patnaik, G.K. 1996. Protective action of ursolic acid against chemical induced hepato-toxicity in rats. Indian Journal of Pharmacology 28: 232-239.
3. Ishak, K.G. 1982. The liver chapter 17th in "Pathology of drug induced and Toxic disease", Riddell RH, New York: Churchill Livingstone.
4. Yoshigurki, M., Toshihara, H., Shoji, A. 1992. High molecular weight protein aggregates formed in the liver of paracetamol treated rats. Journal of Pharmacy and Pharmacology 44: 932-937.
5. Nanji, A.A., Jokelainen, K.J., Fotouhinia, N. 2000. Increased severity of alcoholic liver injury in female rats: role of oxidative stress, endotoxin and chemokines. American Journal of Physiology 281:1348-1356.
6. Kasahara, Y. 1977. Spleno-hepatoplasty in rats with chemically induced cirrhosis of the liver. Archivum Japonicum Chirurgicum 46:335-360.
7. Henry, J.B. 1974. Clinical diagnosis and management by laboratory methods, W.B. Saunders and Co., Philadelphia.
8. Bergmeyer, H.U., Scheibe, P. wahlefeld, A.W. 1978. Optimization methods for aspartate aminotransferase and alanine aminotransferase. Clinical Chemistry Journal 24(1):58-73.
9. Bowers, G.N., McComb, R.B. 1966. A continuous spectrophotometric method for measuring the activity of serum alkaline Phosphatase. Clinical Chemistry Journal 12:70-89.
10. Szasz, G. 1969. A kinetic photometric method for serum gamma-glutamyl transpeptidase. Clinical Chemistry 15(2):124-136.
11. Jendrassik, L., Grof, P. 1938. Simplified photometric methods for the determination of the blood bilirubin. Biochemische Zeitschrift 297: 81-89.
12. Weichselbaum, T.E. 1946. Quantitative colorimetric determination of total protein in serum. American Journal of Clinical Pathology 7: 40-42.
13. Dumas, B.T., Watson, W.A., Biggs, H.G. 1971. Albumin standards and the measurement of serum albumin with bromocresol green. Clinica Chimica Acta. 31 (1):87-96.
14. Finely, P.R., Schifman, R.B., Williams, R.J., Licht, D.A. 1978. Cholesterol in high-density lipoprotein: use of Mg²⁺/dextran sulfate in its enzymatic measurement. Clinical Chemistry 24:931-933.
15. Flegg, H.M. 1973. Quantitative-enzymatic-colorimetric determination of total and HDL-C in serum or plasma. Annals of Clinical Biochemistry pp.10 - 79.
16. Fredrickson, D.S., Levy, R.I. Lees, R.S. 1967. Quantitative enzymatic-

Clinicopathological study on some hepatotoxins

- colorimetric determination of triglycerides in serum. *New England Journal of Medicine* 276: 64.
17. Trinder, P. 1969. Determination of glucose in blood using glucose oxidase with an alternative oxygen acceptor. *Annals of Clinical Chemistry* 6: 24-33.
 18. Bancroft, J.D., Stevens, A., Turner, D.R. 1996. *Theory and practice of histological techniques*. Fourth Ed. Churchill Living stone, New York, London, San Francisco, Tokyo.
 19. Franklin, C.C., Krejsa, C.M., Pierce, R.H., White, C.C., Fausto, N., Kavanagh, T.J. 2002. Caspase-3-dependent cleavage of the glutamate-L-cysteine ligase catalytic subunit during apoptotic cell death. *American Journal of Pathology* 160: 1887-1894.
 20. Bonkovsky, H.L., Kane, R.E., Jones, D.P., Galinsky, R.E., Banner, R. 1994. Acute hepatic and renal toxicity from low doses of acetaminophen in the absence of alcohol abuse or malnutrition: evidence for increased susceptibility to drug toxicity due to cardiopulmonary and renal insufficiency. *Hepatology* 19(5): 1141-1448.
 21. Sreedhar, V., Nath, L.K., Nath, M.S., RajaSekhar, K.K., Shankarananth, V. 2011. Hepatoprotective Activity of *Vitex trifoliata* roots against Paracetamol-Induced Hepatic Injury in rats. *Journal of Pharmacy Research* 4(2): 551-553.
 22. Diadelis, R., Jan, N.M., Commandeur, E.D., Nic, P.E., Vermeulen. 1995. Mechanism of protection of Lobenzarit against paracetamol-induced toxicity in rat hepatocytes *Environmental Toxicology and Pharmacology Section* 293: 300.
 23. Fouada, A.A., Jresatb, I. 2012. Hepatoprotective effect of coenzyme Q10 in rats with acetaminophen toxicity. *Environmental Toxicology and Pharmacology* 33(2): 158-167.
 24. Kanchana, N., Sadiq, A.M. 2011. Hepatoprotective effect of plumbago zeylanica on paracetamol induced liver toxicity in rats. *International Journal of Pharmacy and Pharmaceutical Sciences* 3(1): 0975-1491.
 25. Iweala, E.E.J., Osundiya, A.O. 2010. Biochemical, Haemayological and Histological Effects of Dietary Supplementation with leaves of *Gnetum africanum Welw* on Paracetamol induced Hepatotoxicity in rats. *International Journal of Pharmacology* 6(6): 872-879.
 26. Setty, S.R., Quereshi, A.A., Swamy, A.H., TusharPatil, T., Prakash, T., Prabhu, K., Gouda, A.V. 2007. Hepatoprotective activity of *Calotropis procera* flowers against paracetamol-induced hepatic injury in rats. *Fitoterapia* (78):451-454.
 27. Raj Kapoor, B.; Venugopal, Y.; Anbu, J.; Harikrishnan, N.; Gobinath, M. and Ravichandran, V. 2008. Protective effect of *Phyllanthus polyphyllus* on acetaminophen induced hepatotoxicity in rats. *Pakistan. J. Pharm. Sci.*, 21(1): 57 - 62.
 28. Nicholson, D.W., Ali, A., Thornberry, N.A. 1995. Identification and inhibition of the ICE/CED-3 protease necessary for mammalian apoptosis. *Nature* 376: 37-43.
 29. Mohammed, H.M. 2008. Advances in Dietary Enrichment with N-3 Fatty Acids. *Critical Reviews in Food Science and Nutrition* 48(5): 402-410.
 30. Tipoe, G.L., Ho, C.T., Liong, E.C., Leung, T.M., Lau, T.Y., Fung, M.L., Nanji, A.A. 2009. Voluntary oral feeding of rats not requiring a very high fat diet is a clinically relevant animal model of non-alcoholic fatty liver disease (NAFLD): *Histology Histopathology* 24(9): 1161-1169.
 31. Latimer KS, Mahaffey EA, Prasse KW, eds. Duncan & Prasse's 2003. *Veterinary*

- Laboratory Medicine: Clinical Pathology, 4th ed. Ames, Iowa: Iowa State University Press.
32. Yuan, G., Gong, Z., Zhou, X., Zhang, P., Sun, X., Li, X. 2006. Epigallocatechin-3-Gallate Ameliorates Alcohol-Induced Liver Injury in Rats. *International Journal of Molecular Sciences* 7: 204-219.
 33. Aguilera, A.A., Diaz, G.H., Barcelata, M.L., Guerrero, O.A., Ros, R.M. 2004. Effects of fish oil on hypertension, plasma lipids, and tumor necrosis factor- α in rats with sucrose-induced metabolic syndrome. *Journal of Nutrition and Biochemistry* 15(6): 350-357.
 34. Meziane, R.K., Khemmar, L., Amamou, F., Yazit, M., Didi, A., Chabane-Sari D. 2012. Anti-obesity and anti-hyperlipidemic effect of *Citrullus colocynthis* oil in the offspring of obese rats. *Annals of Biological Research* 3(5): 2486-2490.
 35. Nestel, P.J. 2000. Fish oil and cardiovascular disease: lipids and arterial function. *American Journal of Clinical Nutrition*. 71(1): 228-231.
 36. Bruck, R., Aeed, H., Avni, Y., Shirin, H., Matas, Z., Shahmurov, M. 2004. Melatonin inhibits nuclear factor kappa B activation and oxidative stress and protects against thioacetamide induced liver damage in rats. *Journal of Hepatology* 40(1): 86-93.
 37. Kowalczyk, E., Kopff, A., Fijalkowski, P., Kopff, M., Niedworok, J., Smigielski, J., Blaszczyk, J., Kedziora, J., Tyslerowicz, P. 2003. Effect of anthocyanins on selected biochemical parameters in rats exposed to cadmium. *Acta Biochimica Polonica* 50(2): 543-601.
 38. Martin, P., Friedman, L.S. 1998. Assessment of liver function and diagnostic studies In. *Handbook of liver Disease*. Ed. Friedman LS, Keeffe EB and Maddery WC. London, Churchill, Livingstone.
 39. Ebrahim, A.T., Ahkam, M., El-Gendy, A.M., El-Zawahry, B. 2004. Antihepatotoxic potential of ginseng (*Panax ginseng*) in thioacetamide-induced acute hepatocellular injury in rats. *Egyptian Journal of Hospital Medicine* 16: 55 - 64.
 40. Alkiyumi, S.S., Abdullah, M.A., Alrashdi, A.S., Salama, S.M., Abdelwahab, S.I., Hadi, A.H. 2012. *Ipomoea aquatica* Extract Shows Protective Action against Thioacetamide Induced Hepatotoxicity. *Molecules* 17: 6146-6155.
 41. Al-Attar, A.M. 2011. Hepatoprotective Influence of Vitamin C on Thioacetamide-induced Liver Cirrhosis in Wister Male Rats. *Journal of Pharmacology and Toxicology* 6: 218-233.



التغيرات البيوكيميائية والهستوباثولوجية والهستوكيميائية المناعية فى الفئران المعالجة بكل من الباراسيتامول وزيت السمك والثيوسيتاميد.

فاطمة عبد المنعم جاد¹، أسامة على محمد عبد الله²، أيمن سمير فريد¹، خالد محمد مصطفى فراره¹
¹ قسم الباثولوجيا الإكلينيكية - كلية الطب البيطرى - جامعة بنها، ² قسم الباثولوجيا الإكلينيكية - كلية الطب البيطرى - جامعة قناة السويس

المخلص العربي

أجريت هذه الدراسة لمعرفة ومقارنة التغيرات البيوكيميائية والهستوباثولوجية والهستوكيميائية المناعية لإصابات الكبد المختلفة والتي تشمل التهاب الكبد والتشمع الكبدي وتليف الكبد. وقد تم استخدام 6 مجموعات من الفئران 3مجموعات تم معالجتها بكل من الباراسيتامول كجرعة واحدة وزيت السمك والثيوسيتاميد لمدة 8 أسابيع وأيضاً 3 مجموعات أخرى استخدمت كمجموعات ضابطة لتلك المجموعات. وقد وجد زيادة فى نشاط إنزيم الألبين أمينو ترانس فريز وإنزيم الأسبرتيت أمينو ترانس فريز والبليروبين الكلى فى الثلاث مجموعات المعالجة وعلاوة على ذلك وجد زيادة فى إنزيم الألكالين فوسفاتيز وإنزيم جاما جلوتاميل ترانس فريز وعلى العكس نقص فى البروتينات الكلية والألبومين فى مجموعة الثيوسيتاميد. وقد وجد أيضاً اضطرابات فى مستوى الدهون والجلوكوز فى الثلاث مجموعات المعالجة. لذلك فقد تبين من نتائج هذه الدراسة أن كل من الباراسيتامول وزيت السمك والثيوسيتاميد لهم تأثير سام ومدمر على الكبد.

(مجلة بنها للعلوم الطبية البيطرية: عدد 25(1):18-28, سبتمبر 2013)