*Original Paper***Clinical, haemato-biochemical and ultrasonographic diagnostic tools of different urinary tract affections in dogs**Youssef M. Y. Elgazzar¹, Mohamed M. Ghanem¹, Yassein M. Abdel-Raof¹, Mahmoud A. Y. Helal^{1*}¹Department of Animal Medicine, Faculty of Veterinary Medicine, Benha University, Egypt**ARTICLE INFO****Keywords**

Cystitis
Hydronephrosis
Renal failure
Ultrasonography
Urinary affections

Received 17/01/2021**Accepted** 15/02/2021**Available On-Line**

01/04/2021

ABSTRACT

Urinary tract affections are important clinical problems recorded in dogs affecting their health condition. The present study was carried out on 21 dogs of both sexes and different breeds having different urinary tract affections. The study aimed to evaluate clinical, hematological, biochemical, urinalysis, and ultrasonographic changes in dogs with different urinary tract affections. Acute renal failure, hydronephrosis, polycystic kidney disease, urolithiasis, and cystitis were diagnosed in 5,3,3,5,5 dogs, respectively. The most common clinical signs recorded in all affections were pollakiuria, hematuria, polyuria, dysuria, urine retention. Urinalysis showed the presence of proteinuria, blood in different affections of the urinary tract. There was decrease in RBCs count and Hemoglobin content above normal reference value in all urinary tract affections except in cystitis and there was increase in WBCs count above normal reference value in all different urinary tract affections. There was increase in urea and creatinine levels above normal reference value in all urinary tract affections except in cystitis. There were no changes in ALT, and AST levels in all affections except in acute renal failure were higher than normal reference value. Ultrasonographic examinations revealed structural abnormalities in all recorded urinary tract affections. The results of the present study revealed that clinical, hematological, biochemical, urinalysis, and ultrasonographic examinations are essential in dogs for accurate diagnosis of different urinary tract affections.

1. INTRODUCTION

The urinary system has an important role in the elimination of waste products and maintenance of electrolyte balance. Any disorder of the urinary system can cause metabolic disturbances and acid-base imbalance (Dehmiwal et al., 2015). Kidney diseases are common in small animals and are usually associated with poor prognosis in the late stages (Kovarikova, 2015).

Diagnosis of acute renal failure is usually based on the combination of appropriate history, clinical examination, laboratory data, and ultrasound examination. The minimum database for kidney affection includes BUN, creatinine, urinalysis, CBC, ultrasonography which is noninvasive and very useful for detection and characterization of renal parenchymal structure. It is the technique of choice for accurate diagnosis of fluid-filled cystic lesions, renal mass lesions, hydronephrosis, and urolithiasis (Kumar et al., 2011).

Hydronephrosis refers to dilation of the renal pelvis and calyces resulting in progressive atrophy and cystic enlargement of renal parenchyma which leads to atrophy of the renal parenchyma and loss of function (Santarosa et al., 2007). Hydronephrosis results from outflow obstruction of the ureter, bladder, or urethra. Obstruction finally destroys kidney function because of increased ureteral pressure and decreased renal blood flow leading to cellular atrophy and necrosis. Abdominal masses compressing the ureter,

ureteral neoplasia, ureteral calculi, accidental ligation of the ureter are common causes of unilateral hydronephrosis (Helal, 2005).

Polycystic kidney disease is defined as a genetically determined cystic lesion of either the autosomal-dominant form or autosomal recessive form. Polycystic kidney disease is classified as solitary or multiple inherited or acquired and simple or complicated (Nyland and Mattoon, 2014). These cysts can multiply in numbers and grow in size over time, causing severe damage to kidney tissue and leads to kidney failure (Wills et al., 2009). Ultrasonography is the technique of choice for the diagnosis of polycystic kidney disease, Simple renal cysts have specific ultrasonographic images consisting of a well-defined cavity with anechoic content, strong distal acoustic enhancement, and sharp demarcation (VanDyck et al., 2018).

Urolithiasis is another common disease condition in small animals which is defined as the formation of sediment anywhere within the urinary tract which consists of one or more poorly soluble urine crystalloids (Tion et al., 2015). It is a multifactorial condition due to combined influences of physiological, nutritional, and managemental factors. Calculus formation is a complex process that occurs due to successive physiochemical events such as supersaturation, nucleation, growth, aggregation, and retention within the renal tubules (Yadav et al., 2011). Accurate diagnosis of urolithiasis cannot be depending on history, clinical signs, hematology, urinalysis, and other findings without

* Corresponding author: Mahmoud A. Y. Helal, Dep. of animal medicine faculty of veterinary medicine Benha University – Moshtohor, Kalyobiya 13736, Egypt. E mail: mahmoudatef75@yahoo.com

diagnostic imaging. So, for dogs with lower urinary tract signs, ultrasound examination is crucial when clinical signs persist or recurrent due to abdominal ultrasonography having 90% sensitivity, 98% specificity, and 97% accuracy (Fromsa and Saini, 2019).

Cystitis is one of the common affections of the urinary bladder caused by bacterial infection in dogs and more frequent in females than in males due to ascending fecal bacterial contamination of the vulva, peri vulvar skin, the vestibule (Ramezani et al., 2012). The causes of cystitis in dogs are multifactorial as cystic calculi, tumor, nervous and endocrinological disorders. Common clinical signs in the case of cystitis in dogs include pollakiuria, bloody urine, fever, dullness, abdominal pain, and anorexia (Hedia et al., 2019). The methods for diagnosis of cystitis include clinical examination, urinalysis, complete blood cell count and serum biochemical analysis, and ultrasonographic examination (Ramezani et al., 2012). Therefore, this study was planned to evaluate clinical, hematological, biochemical changes, urinalysis, and ultrasonographic efficacy in the diagnosis of different urinary tract affections in dogs.

2. MATERIAL AND METHODS

2.1 Animals:

This study was undertaken on 21 dogs of different sexes (16 male and 5 female), ages (2-11 years), and breeds including German Shepherd (n=7), Golden Retriever (n=3), Labrador Retriever (n=3), Doberman (n=4), Cocker spaniel (n=3), and Yorkshire shire (n=1) belonged to pet animal veterinary clinic of faculty of veterinary medicine, Benha University and private pet animal clinics located in Cairo governorate, Egypt. Five male dogs were affected with acute renal failure, three male dogs were affected with hydronephrosis, three male dogs were affected with polycystic kidney disease, five male dogs were affected with urolithiasis, and five female dogs were affected with cystitis. All examinations were done after the approval of the Ethics committee of Benha University with the approval number (BUFVTM04032020).

2.2 Urine examination:

Urine samples were collected by using urethral catheterization (Kelly, 1984) and analysis was made by using commercial urine strips (COMBI-9 strips Produced by Pasteur Lab, Egypt).

2.3 Hematological examination:

Total erythrocytic count (RBCs), hemoglobin concentration (Hb), packed cell volume (PCV), total leukocytic count (WBCs), and differential leukocytic count were determined by hematological analyzer (Model No.93-91098-00-GF) as previously described by Feldman et al., (2000). Results were compared with normal reference values (Latimer.,2011).

2.4 Biochemical analysis:

Serum urea and creatinine concentration were determined spectrophotometrically using special kits according to the method described by Walker, (1990); Peake and Whiting, (2006); respectively. ALT and AST were determined spectrophotometrically by using the special kits according to the method described by Thefeld (1974); Pagana and Pagana (2017); respectively. Results were compared with normal reference value (Latimer.,2011).

2.5 Ultrasonographic examination:

Ultrasonographic examinations of kidneys and urinary tract in all cases were done according to Penninck and D'Anjou (2015).

3. RESULTS

3.1 Clinical findings:

All the following data are represented in Table (1) and Table (2). Total cases of acute renal failure were admitted with a history of vomiting, diarrhea, inappetence, and polyuria, polydipsia, dehydration, clinical examination revealed that temperature was $38.5^{\circ}\text{C}\pm 0.5$, pulse rate was 90 ± 5 (beat/min.) and respiratory rate was 20 ± 5 (breath/min.) with slightly pale visible mucous membrane and normal superficial lymph nodes. Total cases of hydronephrosis were admitted with a history of loss of appetite, abdominal pain, swollen abdomen, hematuria, dysuria, and clinical examination revealed that temperature was $38.5^{\circ}\text{C}\pm 0.5$, pulse rate was 128 ± 5 (beat/min.) and respiratory rate was 24 ± 5 (breath/min.) with no abnormalities in visible mucous membrane and superficial lymph nodes. Total cases of polycystic kidney disease were admitted with a history of constipation, abdominal pain, weight loss, vomiting, pollakiuria, polyuria, and clinical examination revealed that temperature was $38.5^{\circ}\text{C}\pm 0.5$, pulse rate was 92 ± 5 (beat/min.) and respiratory rate was 20 ± 5 (breath/min.) with pale visible mucous membrane and normal superficial lymph nodes. Total cases of urolithiasis were admitted with a history of abdominal pain, urine retention, dysuria, hematuria, straining during urination and licking around the urinary opening, clinical examination of dogs revealed that temperature was $38.9^{\circ}\text{C}\pm 0.5$, pulse rate was 125 ± 5 (beat/min.), and respiratory rate was 23 ± 5 (breath/min.) with no abnormalities in visible mucous membrane and superficial lymph nodes. Total cases of cystitis were admitted with a history of inappetence, abdominal pain, and pollakiuria, by clinical examination the temperature was $40^{\circ}\text{C}\pm 0.5$, pulse rate 120 ± 5 (beat/min.), and respiratory rate 25 ± 5 (breath/min.) and no abnormalities in visible mucous membrane and superficial lymph nodes.

Table 1 Clinical examination of different urinary tract affections in dogs

	Acute renal failure N=5	Hydronephrosis N=3	Polycystic kidney disease N=3	Urolithiasis N=5	Cystitis N=5
Temp. ($^{\circ}\text{C}$)	38.5 ± 0.5	38.5 ± 0.5	38.5 ± 0.5	39.9 ± 0.5	40.0 ± 0.5
Pulse rate (beat/min.)	90 ± 5	128 ± 5	92 ± 5	125 ± 5	120 ± 5
Respiratory rate (breath/min)	20 ± 5	24 ± 5	20 ± 5	23 ± 5	25 ± 5
Mucous membrane color	Slightly pale	Rosy red	Pale	Rosy red	Rosy red
Superficial lymph nodes	Normal	Normal	Normal	Normal	Normal

Table 2 Frequency of clinical signs recorded in different urinary tract affections in dogs

Clinical signs	No. of cases	Percentage
Polyuria	9/21	42.9%
Polydipsia	9/21	42.9%
Hematuria	8/21	38.09%
Dysuria	18/21	85.7%
Pollakiuria	16/21	76.19%
Abdominal pain	14/21	66.66%
Inappetence	16/21	76.19%
Weight loss	3/21	14.28%
Vomiting	2/21	9.5%
Diarrhea	3/21	14.28%

3.2 Urinalysis:

All the following data are represented in Table (3). The dogs with acute renal failure had straw yellow-colored urine, pH 7 with the presence of protein. The dogs affected with hydronephrosis had yellow-colored urine, pH 7 with the presence of protein, blood cell. The dogs affected with polycystic kidney disease had yellow-colored urine with pH 6.5. The dogs affected with urolithiasis had red color urine with pH 7 with the presence of protein, Blood. Urine analysis of dogs affected with cystitis revealed that urine had a yellow color, urine pH was 6.5 with the presence of Blood.

3.3 Hematological findings:

All the following data are represented in Table (4). The mean value of RBCs count and Hb content were within the normal reference value in the dogs affected with cystitis. The mean value of RBCs count and Hb content were lower than the normal reference value in dogs affected with acute renal failure, hydronephrosis, polycystic kidney disease, and urolithiasis. The mean value of WBCs count was higher than the normal reference value in dogs affected

with acute renal failure, hydronephrosis, polycystic kidney disease, urolithiasis, and cystitis. The mean value of PCV% was within the normal reference value in all different affections. The mean value of neutrophils was higher than the normal reference value in all different affections. The mean value of lymphocytes was lower than the normal reference value in all different affections except in cystitis. The mean value of Basophil, Eosinophil and monocyte were within the normal reference value in all different affections.

3.4 Biochemical parameters:

All the following data are represented in Table (5). The mean value of urea and creatinine were higher than the normal reference value in dogs affected with acute renal failure, hydronephrosis, polycystic kidney disease, and urolithiasis but the mean value of urea and creatinine were within the normal reference value in dogs affected with cystitis. The mean value of ALT and AST were within the normal reference value in all different affections except in acute renal failure were higher than the normal reference value.

Table 3 Urinalysis of different urinary tract affections in dogs

	acute renal failure N= 5	Hydronephrosis N= 3	Polycystic kidney disease N= 3	Urolithiasis N=5	Cystitis N=5	Reference value
Color	Light yellow	Yellow	Yellow	Red	Yellow	Straw yellow
pH	7	7	6.5	7	6.5	6.5- 7
Protein	++	+	-	+	-	-
Glucose	-	-	-	-	-	-
Bilirubin	-	-	-	-	-	-
Ketone	-	-	-	-	-	-
Blood	-	+	-	+	+	-
Nitrite	-	-	-	-	-	-

Table 4 Hematological alterations of different urinary tract affections in dogs

Hematological parameters	Acute renal failure N=5	Hydronephrosis N=3	Polycystic kidney disease N=3	Urolithiasis N=5	Cystitis N=5	Reference value
RBCs(10 ⁶ /μl)	4.7 ± 0.145	4.8 ± 0.29	4.77 ± 0.38	4.63 ± 0.45	6.5 ± 0.09	5.5 -8.5
Hb(g/dl)	10.5 ± 0.29	10.2 ± 0.73	10.5 ± 0.26	11.03 ± 0.55	13.3 ± 0.12	12-18
PCV %	49.17 ± 0.83	50.3 ± 1.9	43.67 ± 3.18	42.8 ± 0.93	39.7 ± 1.17	37-57
WBCs(10 ³ /mm ³)	42.2 ± 1.07	40.67 ± 1.9	35.3 ± 1.6	39.5 ± 1.29	30.1 ± 0.06	5.5 – 16.9
Neutrophil %	87 ± 0.58	86 ± 0.58	83 ± 1.5	85 ± 0.58	80.5 ± 0.3	58-80
Lymphocyte%	7 ± 0.58	9 ± 0.58	8 ± 0.58	10 ± 0.58	13 ± 0.58	10-21
Eosinophil %	1 ± 0.58	2 ± 0.58	4 ± 0.58	3 ± 1.5	3.5 ± 0.88	0-9
Basophil %	0.3 ± 0.3	0 ± 0	0.6 ± 0.3	0.6 ± 0.3	1 ± 0	0-1
Monocyte%	3 ± 0.25	5 ± 0.2	2 ± 0.58	4 ± 0.58	3 ± 0.5	2-10

Means High or low level than reference value. * N.B

Table 5 Biochemical analysis of urea, creatinine, ALT and AST of different urinary tract affections in dogs

Biochemical parameters	Acute renal failure N=5	Hydronephrosis N=3	Polycystic kidney disease N=3	Urolithiasis N=5	Cystitis N=5	Reference value
Urea (mg/dl)	118 ± 4.16	76.3 ± 2.3	62.7 ± 1.2	56 ± 8.3	26 ± 5.03	7-27
Creatinine(mg/dl)	8 ± 0.29	7.8 ± 0.5	6.6 ± 0.97	7.6 ± 1.05	1.06 ± 0.23	0.5 – 1.8
ALT (U/L)	128.7 ± 4.26	30.67 ± 3.8	32.3 ± 4.3	30.3 ± 5.5	30.3 ± 5.04	10- 125
AST (U/L)	50.7 ± 2.3	45.3 ± 2.9	47.3 ± 1.2	43 ± 2.5	45.3 ± 2.7	0- 48

Means High or low level than reference value. * N.B

3.5 Ultrasonographic findings:

Ultrasonographic examinations of dogs with acute renal failure showed increase in renal cortical echogenicity with the poor corticomedullary definition (Fig. 1). Ultrasonographic examinations of dogs with hydronephrosis showed that the kidney appeared as a sac filled with hypoechoic fluid, with a rim of parenchyma remaining (Fig.2A), loss of tissue architecture of kidney with loss of corticomedullary definition and dilatation of renal pelvis indicated hydronephrosis (Fig.2B). Ultrasonographic examinations of dogs with polycystic kidney disease showed smooth-walled, well-defined anechoic cysts in the kidney (Fig.3A, B). Ultrasonographic

examinations of dogs with urolithiasis showed a large hyperechoic structure with distal acoustic shadowing present in the urinary bladder (Fig.4A, B). Ultrasonographic examinations of dogs affected with cystitis showed thickened bladder wall, turbid content with corrugation in the wall of the urinary bladder, and clear distinction of the submucosa, muscularis, and serosa (Fig.5).

4. DISCUSSION

Proper diagnosis of urinary tract affections provides the key for the selection of the treatment regimen. Accurate

diagnosis of urinary affections relies on a complete history, clinical signs, hematology, biochemical, urinalysis, and ultrasonographic examination of the urinary tract which become a routine practice in veterinary medicine and become the most frequently used technique in assessing canine pelvic and abdominal cavity (Nyland and Mattoon, 2014).

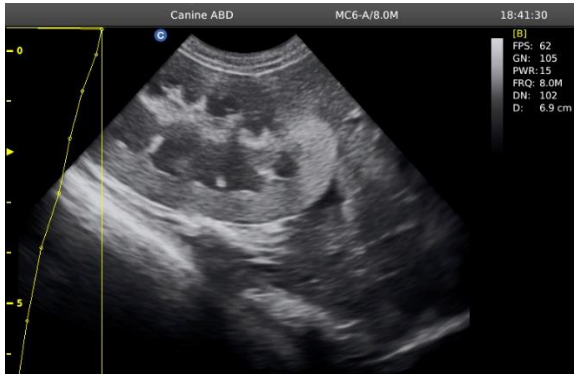

Figure 1 Ultrasonographic examination of kidney showed that increase renal cortical echogenicity(C) as compared to liver echogenicity(L) with poor corticomedullary definition indicating acute renal failure

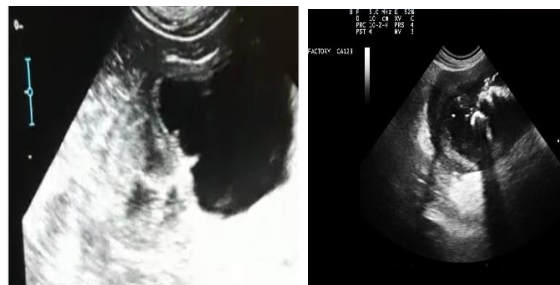


Figure 2 Ultrasonographic image of kidney showing that kidney appeared as sac filled with hypoechoic fluid with a rim of parenchyma remaining indicating hydronephrosis(A), loss of tissue architecture of kidney with loss of corticomedullary definition, dilatation of renal pelvis and dispersed hyperechoic content indicating hydronephrosis (B).

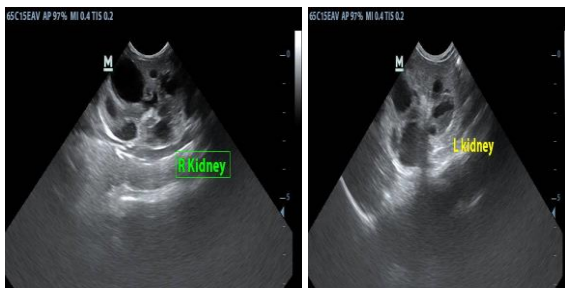


Figure 3 Ultrasonographic image of right kidney(A) and left kidney(B) showing smooth-walled, well defined anechoic cysts(arrow) indicating polycystic kidney disease.

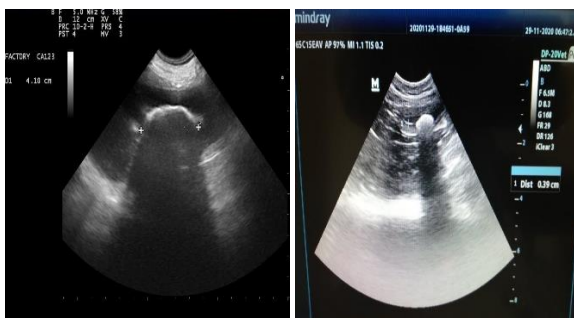

Figure 4 Ultrasonographic image of urinary bladder showing large hyperechoic structure(arrow) with distal acoustic shadowing present in lumen of urinary bladder indicating urolithiasis.

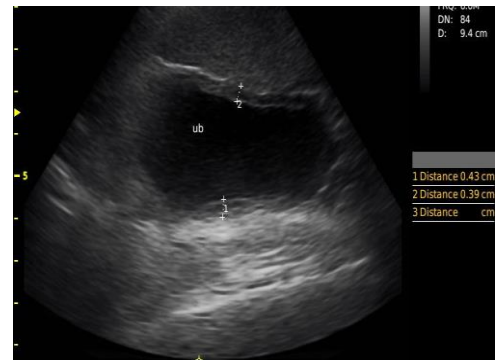


Figure 5 Ultrasonographic image of urinary bladder showing thickened bladder wall (white arrow),turbid content(blue arrow) with corrugated wall of urinary bladder with clear distinction of submucosa, muscularis and serosa indicating cystitis.

The dogs affected with acute renal failure in the present study showed signs of vomiting, diarrhea, inappetence, and polyuria which might be attributed to the accumulation of nitrogenous wastes, metabolic acidosis, and changes in the gastrointestinal tract(Kumar et al.,2011) and these findings were agreeable with Yehia and Salem (2015). The dogs affected with hydronephrosis showed signs of abdominal pain, swollen abdomen, hematuria which might be due to the increased size of the kidney(Stephen et al.,2017) and these findings were similar to Şahal et al., (2005)and Choi et al., (2010). Dogs affected with polycystic kidney disease showed signs of abdominal pain, weight loss, vomiting, and polyuria which might be due to the uremic toxins act centrally to stimulate the chemoreceptor trigger zone which stimulates the vomiting center and renal disease has progressed severe enough to destroy 75% of kidney nephrons lead to decrease urine concentrating ability(Kumar et al.,2011) and these findings were similar to Takahashi et al., (2005). The clinical signs that appeared in dogs affected with urolithiasis include abdominal pain, urine retention, dysuria, hematuria which may be attributed to irritation of bladder mucosa and blockage of the urinary bladder with stone (Fromsa and Saini, 2019) and these findings were agreeable with Chethan et al., (2020). Clinical signs exhibited by dogs affected with cystitis were inappetence, abdominal pain, and pollakiuria which might be due to mucosal irritation or inflammation(Stephen et al.,2017) and these findings were similar to those recorded by Hedia et al., (2019).

Examination of urine sample revealed that presence of protein in the urine of dogs affected with acute renal failure, hydronephrosis, and urolithiasis which might be attributed to decrease glomerular filtration rate which follows the proximal tubular damage which increases the permeability of the filtration barrier which increased filtration of protein in urine lead to proteinuria (Cianciolo et al., 2016), these findings were agreeable with Macanović et al., (2000). Urinalysis in dogs affected with hydronephrosis, urolithiasis, and cystitis revealed the presence of blood in a urine sample which might be attributed to the inflammatory process and occurrence of hematuria (Piech and Wycislo, 2019), these findings were similar to Kumar et al., (2011).

The hematological alterations in dogs affected with acute renal failure include that RBCs count and Hb content were lower than normal reference value due to decreased erythrocyte life span due to accumulation of uremic toxins (Kumar et al., 2011) and WBCs count were higher than the reference value which might be due to stress and dehydration (Helal.,2005), but PCV% was within the normal reference value. The mean value of neutrophils was

higher than normal reference value and the mean value of lymphocytes was lower than normal reference value which might be due to stress and uremia (Fromsa and Saini, 2019). Serum level of urea and creatinine in acute renal failure were higher than normal reference value might be attributed to impaired glomerular filtration and tubular concentrating ability (Vaden et al., 1997), serum level of ALT and AST were higher than normal reference value in dogs affected with acute renal failure which might be due to acute impairment of renal function affects hepatic inflammatory responses, increase vascular permeability of liver and markers of oxidative stress increase lead to increase ALT and AST (Lane et al., 2013) and these results coincided with Schweighauser and Francey (2016). The dogs affected with hydronephrosis had lower level of RBCs count and Hb content than normal reference value which might be due to shortened erythrocyte life span due to accumulation of uremic toxins (Kumar et al., 2011) and higher WBCs count than normal reference value due to the occurrence of infection that occurred due to urine stagnation (Helal, 2005) and PCV% was within normal reference value, also there was a higher neutrophil level and lower lymphocyte level than normal reference value which might be attributed to the occurrence of infection which occurred due to urine stagnation (Helal, 2005), and these findings were similar to Choi et al., (2010). Also, there was increase in serum urea and creatinine level and no increase in serum level of ALT, and AST in dogs affected with hydronephrosis which might be due to the effect of severe degenerative changes with severe cystic dilatation of the renal tubules including proximal, distal and collecting renal tubules so urea and creatinine can't be filtered properly by the kidneys and carried back into the blood lead to increase their level (Arifianto et al., 2020) and these results were similar to Şahal et al., (2005). Polycystic kidney disease includes multiple disorders characterized by one or more grossly visible cystic cavities in the renal parenchyma. If the kidney contains multiple numbers of the cyst, the disorder is usually known as polycystic kidney disease which is recorded in human beings, dogs, and cats (Takahashi et al., 2005). In our study, the dogs affected with polycystic kidney disease had low level of RBCs count and Hb content due to decreased production of erythropoietin hormone which stimulates erythropoiesis and decrease erythrocyte life span due to accumulation of uremic toxins (Kumar et al., 2011) and had high level of WBCs count which might be due to inflammatory process and dehydration (O'Leary et al., 2002), but PCV % was within normal reference value, the mean value of neutrophil was higher than normal reference value, but mean value of lymphocyte was lower than normal reference value which might be attributed to stress and dehydration (O'Leary et al., 2002), there was increase in serum level of urea and creatinine and no increase in serum level of ALT, and AST in dogs affected with polycystic kidney which might be due to impaired glomerular filtration and tubular concentrating ability due to loss of renal function from renal cyst lead to increase level of urea and creatinine (Sarma and Kalita, 2019), and these results were similar to Takahashi et al., (2005). The mean value of RBCs count and Hb content in the dogs affected with urolithiasis had lower level than normal reference value which might be due to the occurrence of hematuria (Tion et al., 2015). There was an increase in WBCs count in the dogs affected with urolithiasis which attributed to stress, inflammation, and infection associated with the obstruction or mucosal damage caused by uroliths (Schultze, 2000), but PCV% level was within normal

reference value. The mean value of neutrophil had higher level and the mean value of lymphocyte had lower level than normal reference value which might be due to stress induced by bacterial organisms in the urinary tract as well as a sign of manifestation of body defense mechanism against bacterial infections (Yogeshpriya et al., 2018) and these findings in accordance with Fromsa and Saini, (2019). The mean value of urea and creatinine had high level in dogs affected with urolithiasis, but ALT and AST were within normal reference value which might be due to post renal uremia due to obstruction of the excretory pathway from cystic calculi (Vijayakumar et al., 1999) and these findings in agreement with Sarma and Kalita, (2019). The present study showed that RBCs count, Hb content, and PCV% were within normal reference value but WBCs count was higher than reference value in dogs affected with cystitis due to inflammatory reaction as a result of bacterial infection (Stephen et al., 2017) and also might be due to presence of localized infection along with hemorrhage in urinary bladder (Sarma and Kalita, 2019). The mean value of neutrophil had higher level than normal reference value which might be due to stress induced by bacterial organisms in the urinary tract (Yogeshpriya et al., 2018) but lymphocytes were within normal reference value. The mean value of urea, creatinine, ALT and AST in dogs affected with cystitis were within normal reference value and these findings were similar to Hedia et al., (2019). Ultrasonographic examination of dogs affected with acute renal failure appeared as increase renal cortical echogenicity as compared with liver with poor corticomedullary definition which might be due to interstitial nephritis and gradual loss of nephron function (Kumar et al., 2011) and these findings were agreeable with Yehia and Salem, (2015). Ultrasonographic examinations of dogs with hydronephrosis showed that the kidney appeared as a sac filled with hypoechoic fluid, with a rim of parenchyma remaining and these findings were similar to Şahal et al., (2005). The dogs affected with polycystic kidney disease showed smooth-walled, well defined anechoic cysts in the kidney by ultrasonographic examination which might be due to congenital causes (Kumar et al., 2011) or might be related to parathyroid hormone and vasopressin hormone (Wang et al., 2008) and these findings in accordance with Yehia and Salem, (2015). Ultrasonographic examinations of dogs with urolithiasis showed a large hyperechoic structure present in the urinary bladder and these findings were similar to Yehia and Salem (2015) and Fromsa and Saini (2019). The most characteristics changes that appeared by ultrasonographic examination in dogs affected with cystitis were thickened bladder wall with turbid content with clear distinction of the submucosa, muscularis, and serosa which might be due to leukocyte infiltration and hemorrhage in all the layers of the bladder wall (Dehmiwal et al., 2015) and these results were similar to Yehia and Salem, (2015) and Hedia et al., (2019).

5. CONCLUSION

Investigations of clinical, Haemato-biochemical, urinalysis, and ultrasonographic alterations are essential diagnostic tools in most urinary tract affections in dogs.

6. REFERENCES

1. Arifianto, D., Adji, D., Sutrisno, B., Rickiawan, N., 2020. Renal Histopathology, Blood Urea Nitrogen and Creatinine Levels of Rats With Unilateral Ureteral Obstruction. Indonesian Journal

- of Veterinary Sciences. 1, 1–9.
2. Chethan, G.E., Behera, S.K., Sarma, K., Prasad, H., Rajesh, J.B., BHOWMIK, A., Chang, L., and BASAIAWMOIT, M., 2020. Diagnosis and therapeutic management of cystolithiasis in a golden retriever dog. *Haryana Vet Journal*, 12(12.1), pp.12-19.
 3. Choi, J., Jang, J., Choi, H., Kim, H., Yoon, J., 2010. Ultrasonographic features of pyonephrosis in dogs. *Veterinary Radiology and Ultrasound* 51, 548–553.
 4. Cianciolo, R., Hokamp, J., Nabity, M., 2016. Advances in the evaluation of canine renal disease. *Veterinary Journal* 215, 21–29.
 5. Dehmiwal, D., Behl, S.M., Singh, P., Tayal, R., Pal, M., Chandolia, R.K., 2015. Diagnosis of urinary bladder diseases in dogs by using two-dimensional and three-dimensional ultrasonography. *Veterinary World* 8, 819–822.
 6. Feldman, B.F., Zinkl, J.C., n.d. Jain, NC 2000. "Schalm's Veterinary Hematology", 5th. Lippincott Williams and Wilkins, Philadelphia, London.
 7. Fromsa, A., Saini, N.S., 2019. Canine Urolithiasis and Concurrent Urinary Bladder Abnormalities: Symptoms, Haematology, Urinalysis and Comparative Radiographic and Ultrasonographic Diagnosis. *Veterinary Medicine – Open Journal* 4, 18–26.
 8. Hassan, H., Zaghawa, A., Aly, M., Kamr, A., Nayel, M. and Abd, M., 2019 Prognostic and diagnostic values of acute phase proteins (APPs) and ultrasonography in experimentally induced bacterial cystitis in dogs. *Tradition and Modernity in Veterinary Medicine*, 5(1), pp.36-47.
 9. Helal, M.A.Y., 2005. Diagnosis of experimentally-induced kidney affections in dogs using ultrasonography and other methods. M.V.Sc.Thesis.2005.Fac.Vet.Med.Benha.Univ.
 10. Kelly, W.R., 1984. *Veterinary clinical diagnosis*. Bailliere Tindall.
 11. Kovarikova, S., 2015. Urinary biomarkers of renal function in dogs and cats: A review. *Veterinarni Medicina*. 60, 589–602.
 12. Kumar, V., Kumar, A., Varshney, A.C., 2011. Ultrasonographic Imaging for Structural Characterization of Renal Affections and Diagnosis of Associated Chronic Renal Failure in 10 Dogs. *ISRN Veterinary Science* 2011, 1–11.
 13. Lane, K., Dixon, J.J., MacPhee, I.A.M., Philips, B.J., 2013. Renohepatic crosstalk: Does acute kidney injury cause liver dysfunction. *Nephrology Dialysis Transplantation* 28, 1634–1647.
 14. Latimer, K.S., 2011. *Duncan and Prasse's veterinary laboratory medicine: clinical pathology*. John Wiley and Sons.
 15. Macanović, M., Lazarević, M., Janković-Zagorčić, A., Đurđević, D., 2000. Serum and urine laboratory analyses in dogs with gentamicin induced acute renal failure. *Acta Veterinaria* 50, 83–92.
 16. Nyland, T.G., Mattoon, J.S., 2014. Chapter 16: 'Urinary Tract.' *Small Anim. Diagnostic Ultrasound*, 557–607.
 17. O'Leary, C.A., Ghodduzi, M., Huxtable, C.R., 2002. Renal pathology of polycystic kidney disease and concurrent hereditary nephritis in Bull Terriers. *Australian Veterinary Journal*. 80, 353–361.
 18. Pagana, K.D., Pagana, T.J., 2017. *Mosby's Manual of Diagnostic and Laboratory Tests-E-Book*. Elsevier Health Sciences.
 19. Peake, M., Whiting, M., 2006. Measurement of serum creatinine—current status and future goals. *Clinical biochemist reviews* 27, 173.
 20. Penninck, D. and d'Anjou, M.A. eds., 2015. *Atlas of small animal ultrasonography*. John Wiley and Sons.
 21. Piech, T.L., Wycislo, K.L., 2019. Importance of Urinalysis. *Veterinary Clinics of North America - Small Animal Practice* 49, 233–245.
 22. Ramezani, N., Soroori, S., Jamshidi, S., Molazem, M., 2012. Three-dimensional power doppler ultrasonographic evaluation of induced cystitis in dogs. *Iranian Journal of Veterinary Surgery* 7, 39–47.
 23. Şahal, M., HAZIROĞLU, R., Özkanlar, Y. and Beyaz, L., 2005. Bilateral hydronephrosis and hydroureter in a young dog. *Ankara Üniv Vet Fak Derg* 52, 193–196.
 24. Santarosa, I.A.M., Godoy, C.L.B. de, Pippi, N.L., Antunes, P.S.P., Rappeti, J.C. da S., Krolkowski, G., Novosad, D., Gheller, V.S., 2007. Ultrasound-guided percutaneous nephrostomy in dogs. *Ciência Rural* 37, 762–768.
 25. Sarma, B.K., Kalita, D., 2019. Changes of haematological and biochemical parameters of canine having urinary system disorders. *International Journal of Chemical Studies* 7, 501–504.
 26. Schultze, A.E., 2000. Interpretation of canine leukocyte responses. *Schalm's Vet. Hematol. 5thEdn*. Lippincott, Williams Wilkins, Philadelphia, pp366–381.
 27. Schweighauser, A., Francey, T., 2016. Ethylene glycol poisoning in three dogs: Importance of early diagnosis and role of hemodialysis as a treatment option. *Schweizer Archiv fur Tierheilkunde*. 158, 109–114.
 28. Stephen J. Ettinger, Edward C. Feldman, E.C., 2017. *Textbook of Veterinary Internal Medicine: Diseases of the dog and the cat, Leukopenia, leukocytosis*.
 29. Takahashi, M., Morita, T., Sawada, M., Uemura, T., Haruna, A., Shimada, A., 2005. Glomerulocystic kidney in a domestic dog. *Journal of Comparative Pathology*. 133, 205–208.
 30. Thefeld, W., 1974. *Annuals of Clinical Biochemistry*. Cited by Woot. Free. 79.
 31. Tion, M.T., Dvorska, J., Saganuwan, S.A., 2015. A Review on urolithiasis in dogs and cats. *Bulgarian Journal of Veterinary Medicine*. 18, 1–18.
 32. Vaden, S.L., Levine, J., Breitschwerdt, E.B., 1997. A retrospective case-control of acute renal failure in 99 dogs. *Journal of veterinary internal medicine / American College of Veterinary Internal Medicine*. 11, 58–64.
 33. VanDyck, R., Fina, C., Buresova, E., Paepe, D., De Wilde, H., Daminet, S., 2018. Successful management of a solitary simple renal cyst in a dog. *Vlaams Diergeneeskundig Tijdschrift*. 87, 134–138.
 34. Vijayakumar, G., Nambi, A.P., Vasu, K., Dhanapalan, P., 1999. Ultrasonographic Diagnosis Of Cystic Calculi in a Dog-A Case Report. *Indian Veterinary Journal* 5, 438–439.
 35. Walker, H.K., 1990. The origins of the history and physical examination in *Clinical Methods: The History, Physical, and Laboratory Examinations*. 3rd Edition. Butterworths.
 36. Wang, X., Wu, Y., Ward, C.J., Harris, P.C., Torres, V.E., 2008. Vasopressin directly regulates cyst growth in polycystic kidney disease. *Journal of the American Society of Nephrology*. 19, 102–108.
 37. Wills, S.J., Barrett, E.L., Barr, F.J., Bradley, K.J., Helps, C.R., Cannon, M.J., Gruffydd-Jones, T.J., 2009. Evaluation of the repeatability of ultrasound scanning for detection of feline polycystic kidney disease. *Journal of Feline Medicine and Surgery*. 11, 993–996.
 38. Yadav, R.D., Jain, S.K., Alok, S., Mahor, A., Bharti, J.P., Jaiswal, M., 2011. Herbal plants used in the treatment of urolithiasis: a review. *International Journal of Pharmaceutical Sciences and Research*. 2, 1412.
 39. Yehia, S.G., Salem, Noha Y., 2015. Ultrasonographic Abnormalities in Canine Urinary and Prostatic Affections. *Research Journal for Veterinary Practitioners* 3, 93–98.
 40. Yogeshpriya, S., Narayana Pillai, U., Ajithkumar, S., Unny, M., 2018. Clinico-Haemato-Biochemical Profile of Dogs with Urinary Tract Infection: A Retrospective Study of 32 Cases (2010-2012). *International Journal of Current Microbiology and Applied Sciences*. 7, 2797–2802.